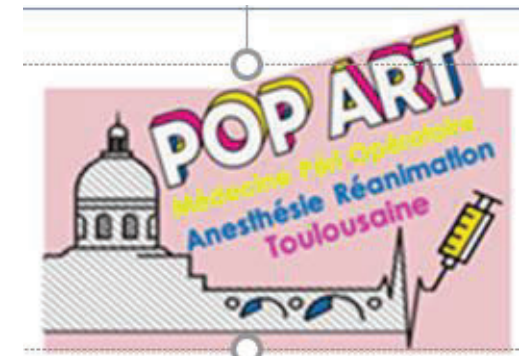

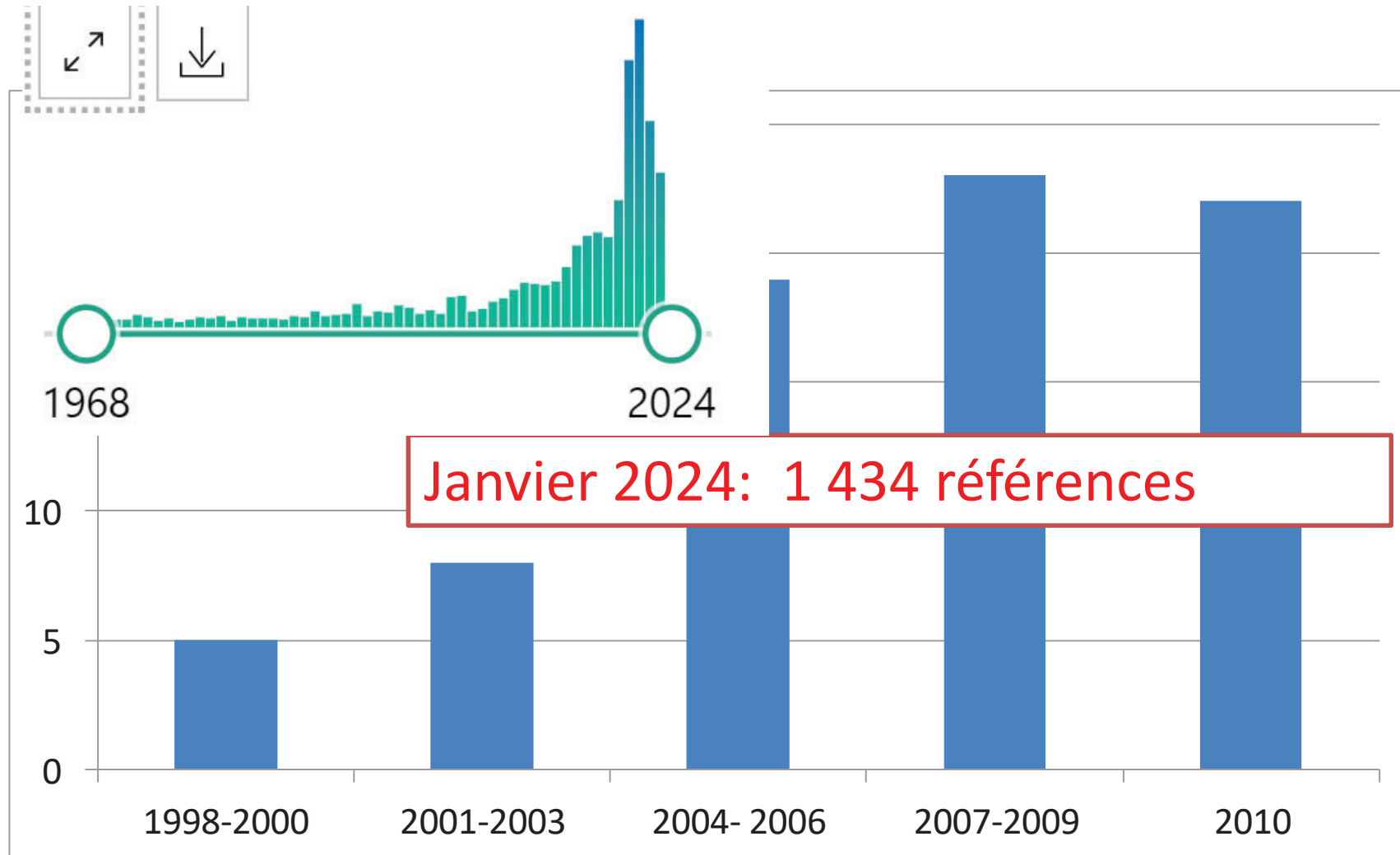


Echo pleuro-
pulmonaire en
réanimation

DU TUSAR 2026
Dr Riu Poulenc (Chu Toulouse)




Lus and bedside



D lichtenstein and lung ultrason >30 références

Réani



Disponible en ligne sur
 ScienceDirect
www.sciencedirect.com

Elsevier Masson France

www.em-consulte.com



MISE AU POINT

Échographie pulmonaire en réanimation et aux urgences

Lung ultrasound in the critically ill

D. Lichtenstein

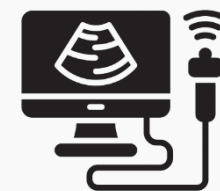Service de réanimation médicale, faculté Paris-Ouest, hôpital Ambroise-Paré, 9, rue Charle



Disponible sur Internet le 26 septembre 2008

Giovanni Volpicelli
Mahmoud Elbarbary
Michael Blaivas
Daniel A. Lichtenstein
Gebhard Mathis
Andrew W. Kirkpatrick
Lawrence Melniker
Luna Gargani
Vicki E. Noble
Gabriele Via
Anthony Dean
James W. Tsung
Gino Soldati
Roberto Copetti
Belaid Bouhemad
Angelika Reissig
Eustachio Agricola
Jean-Jacques Rouby
Charlotte Arbelot
Andrew Liteplo
Ashot Sargsyan
Fernando Silva
Richard Hoppmann
Raoul Breitzkreutz
Armin Seibel

International evidence-based recommendations for point-of-care lung ultrasound





US dans le poumon

- Semblait peu accessible, faible pénétration US ds l'air
- Outil diagnostic: pneumopathie, atélectasie, syndrome interstitiel, pneumothorax, épanchement pleural
- Faible sensibilité RT
- Risque TDM

Nektaria Xirouchaki
Eleftherios Magkanas
Katerina Vaporidi

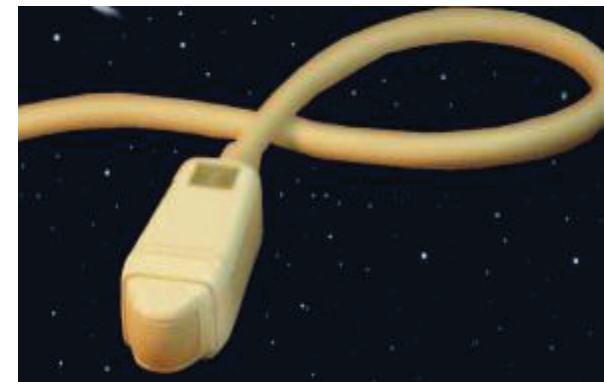
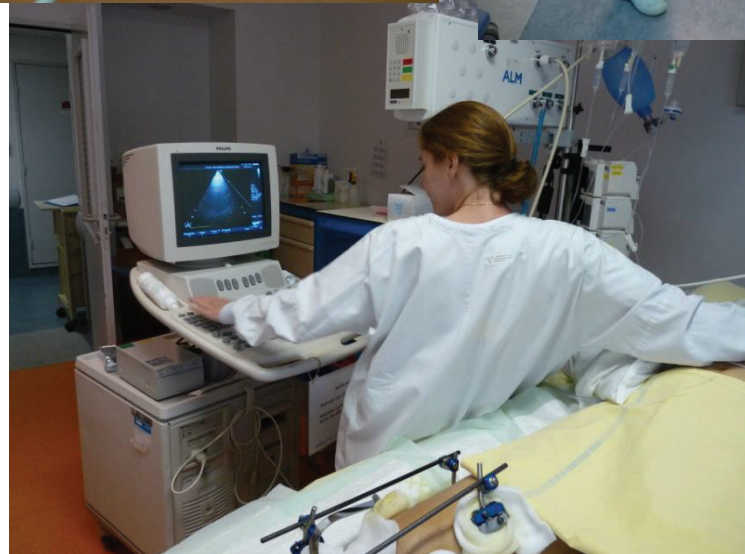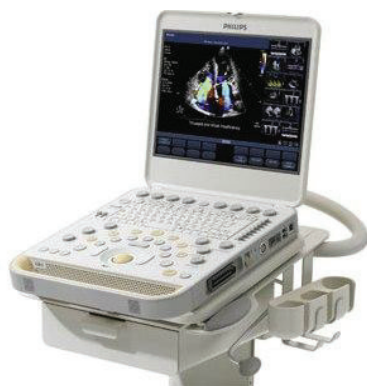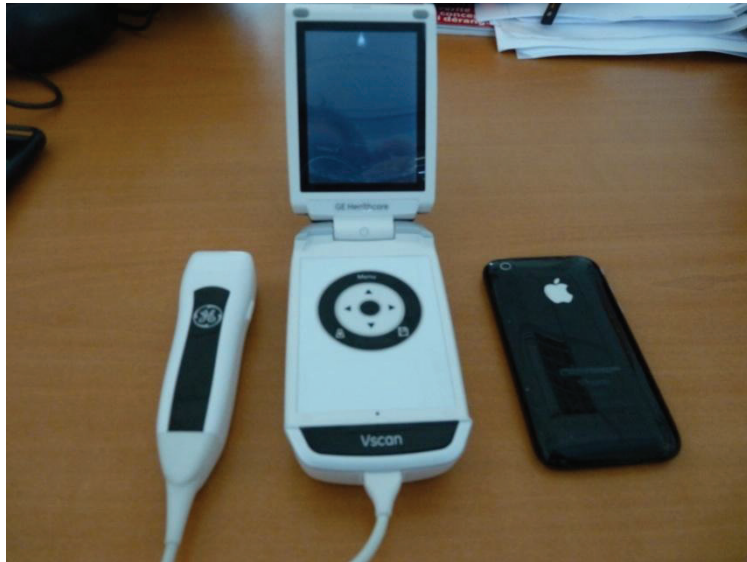Lung ultrasound in critically ill patients: comparison with bedside chest radiography

	consolidation	Sd interstitiel	pneumothorax	Épanchement pleural
	Se : 38 % Sp : 89 % Δc : 49 %	Se : 46 % Sp : 80 % Δc : 58 %	Se : 0 % Sp : 99 % Δc : 89 %	Se : 65 % Sp : 81 % Δc : 69 %
	Se : 100 % Sp : 78 % Δc : 95 %	Se : 94 % Sp : 93 % Δc : 94 %	Se : 75 % Sp : 93 % Δc : 92 %	Se : 100 % Sp : 100 % Δc : 100 %

Un appareil simple

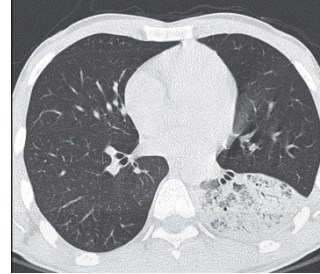
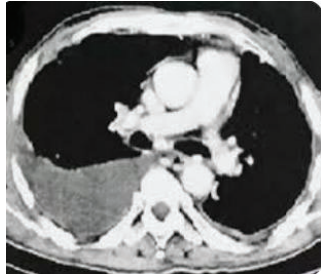
- Compact
- Facilement décontaminable, tactile
- Ni filtre, ni doppler, ni harmonique
- Sonde
- Allumage rapide

L'appareil et la sonde

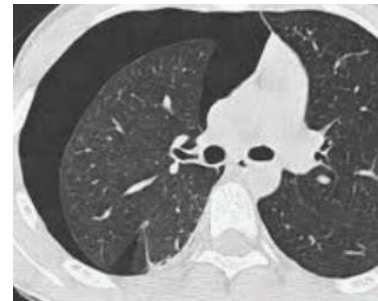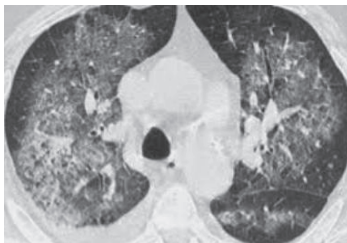


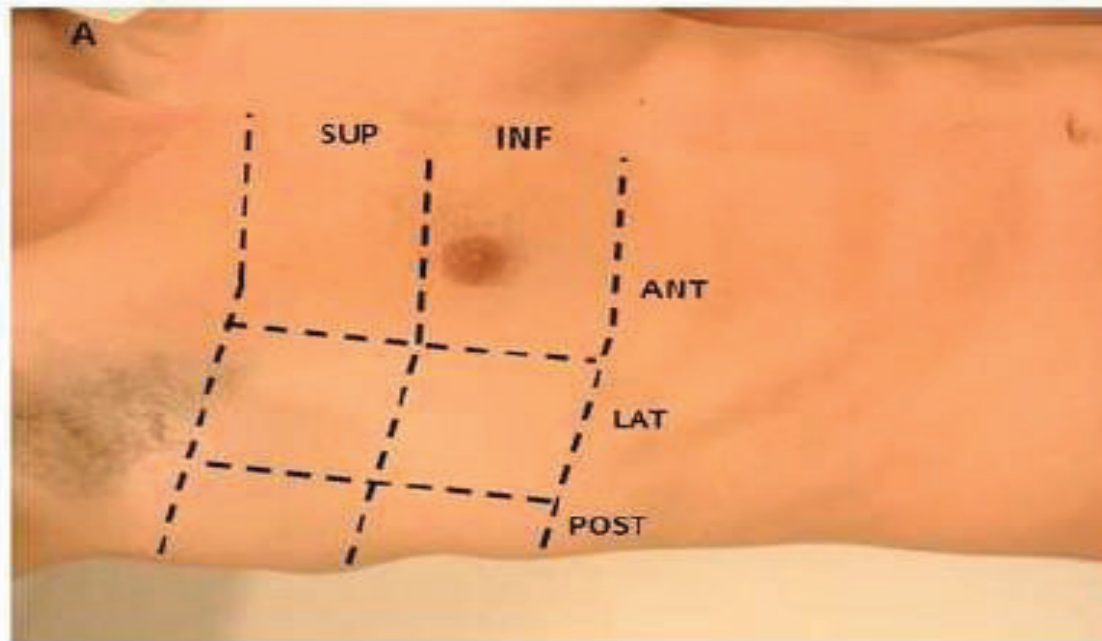
Lieu mélange air eau

- Désordre riche en eau (pleurésie, pneumonie) dans les zones post



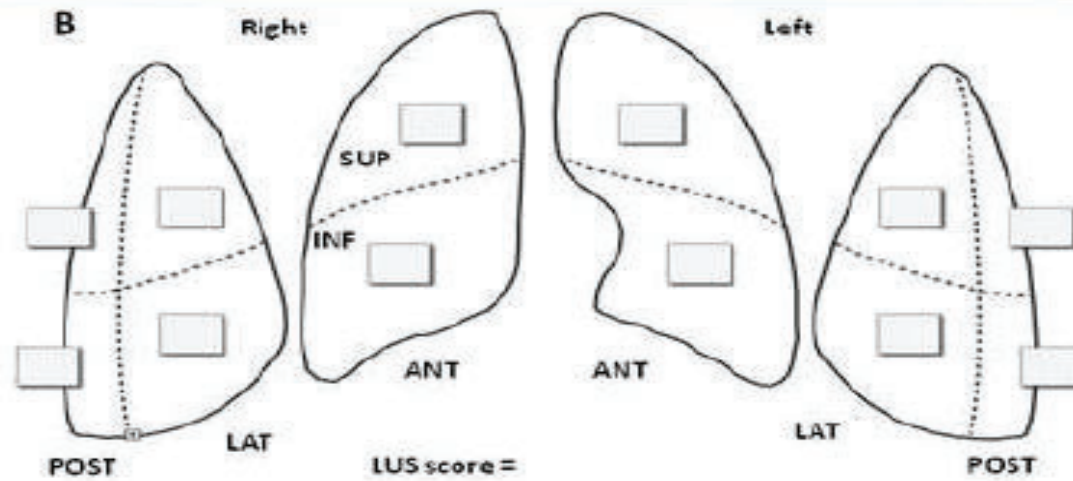
- Désordres riches en air (pneumo, syndrome interstitiel) en antérieur ou latéral





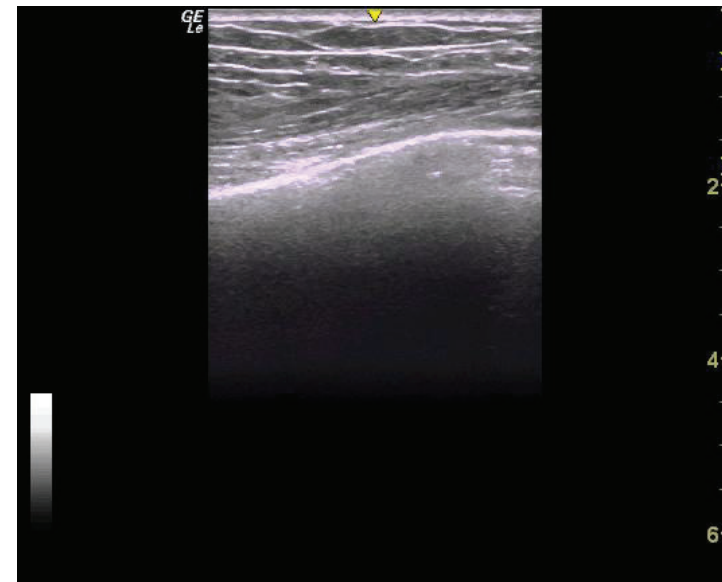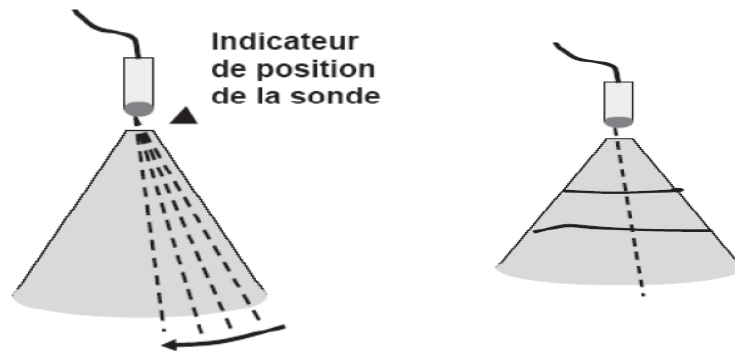
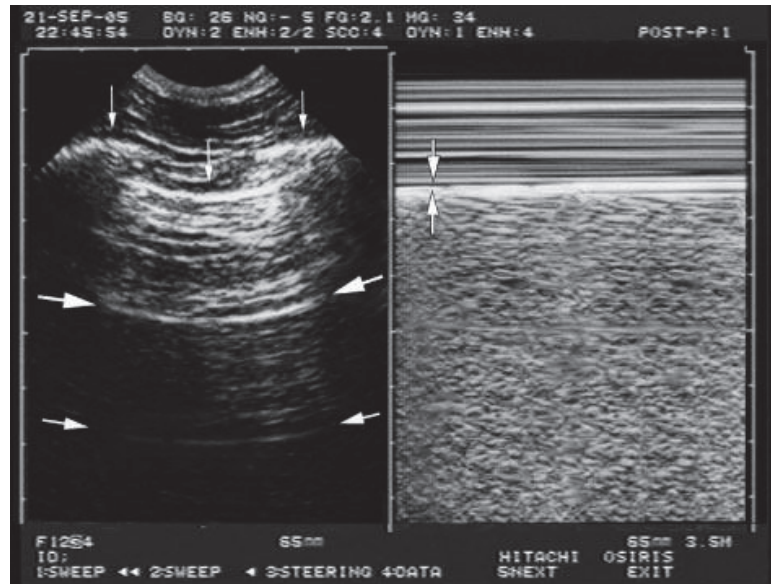
LUS

- 0=normal
- 1=syndrome interstitiel
- 2=Syndrome alvéolo interstitiel
- 3=condensation



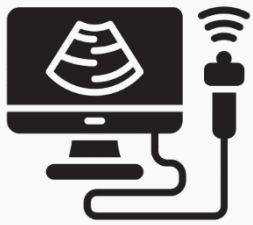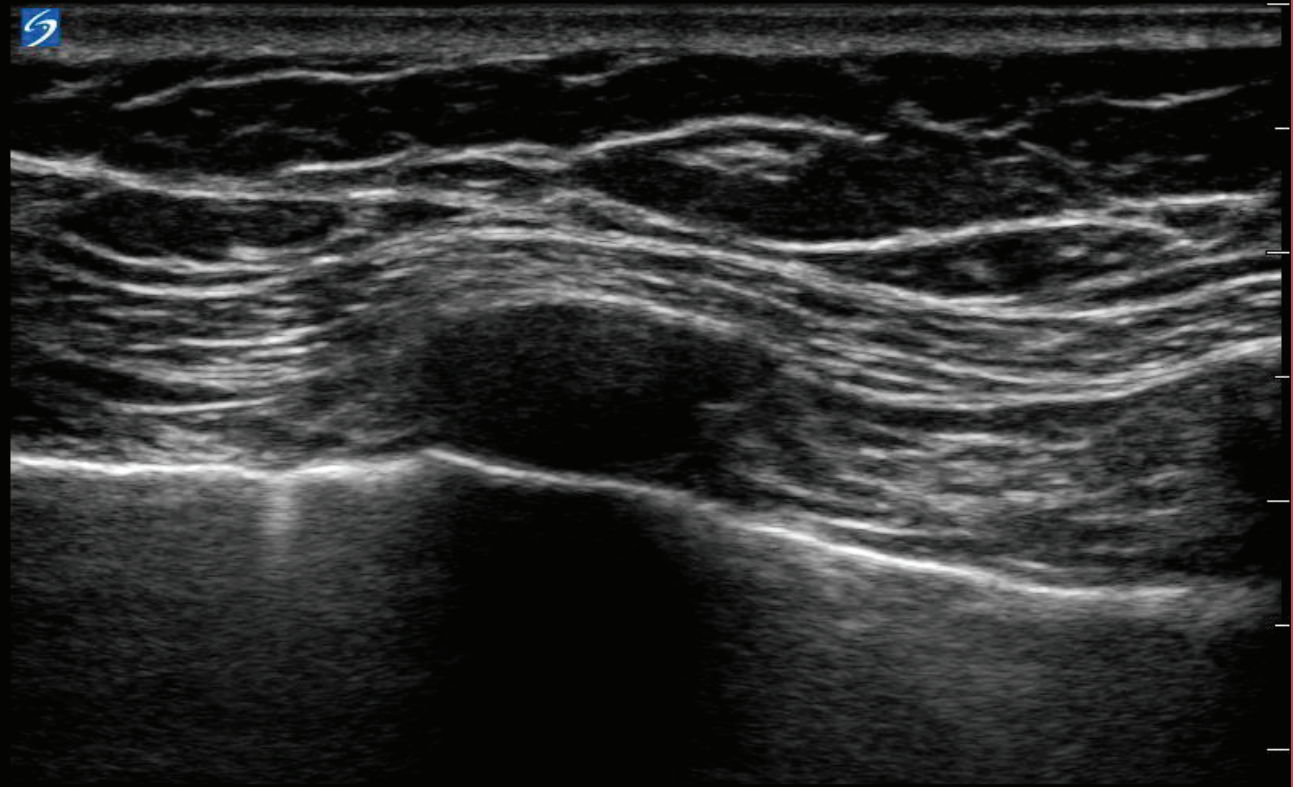
Bouhemad B, rouby JJ, Arbelot C, AJRCCM 2011

La ligne pleurale



Glissement pleural

14 Jan 2014 / 17:57



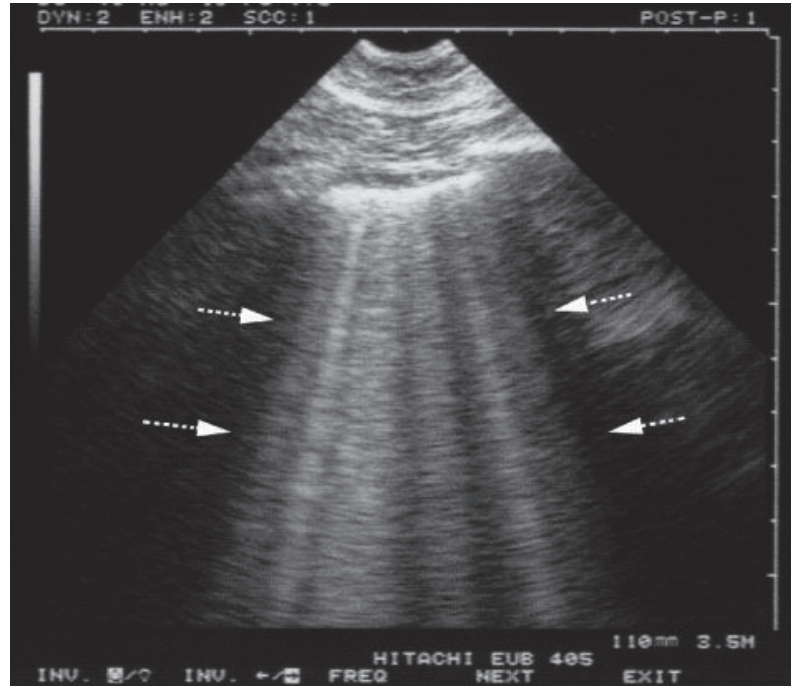
SonoSite
HFL50xp/15-6 Neuro.
IM: 0.6 ITM: 0.2

3.1 cm

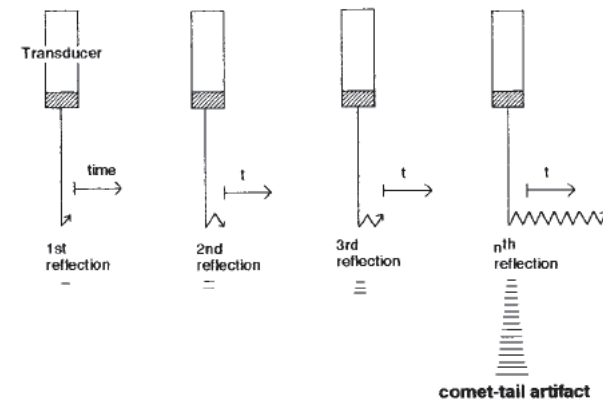
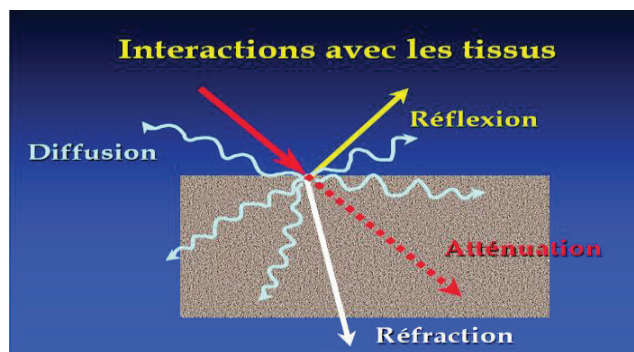
2D: G: 50
PD: 0
MB

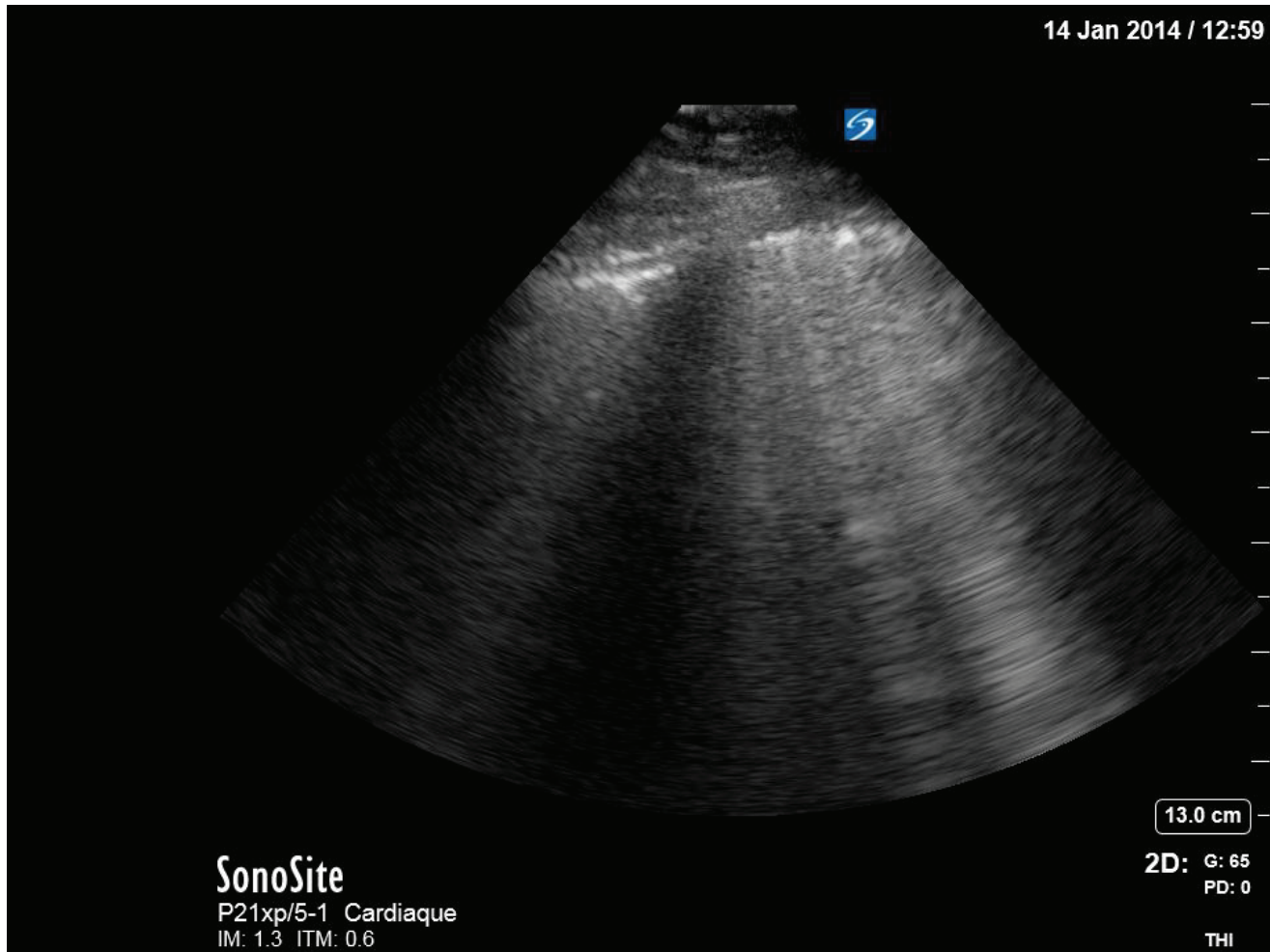
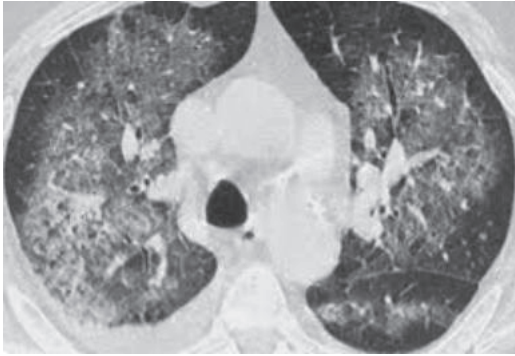
Syndrome interstitiel

Lichtenstein D, . AM J RESPIR CRIT CARE MED 1997;156:1640-1646



- Artéfact en queue de comète (ligne B)
- Naissent de la ligne pleurale
- En rayon laser
- Hyperéchogènes
- Descendant sans épaissements
- Effacent les lignes A
- mobiles





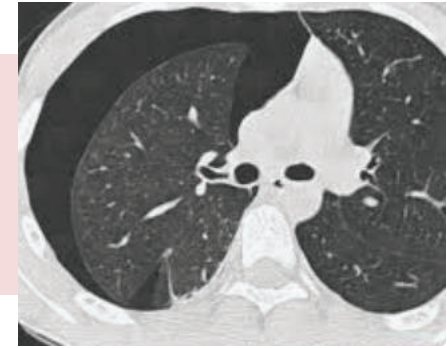SonoSite
P21xp/5-1 Cardiaque
IM: 1.3 ITM: 0.6

13.0 cm
2D: G: 65
PD: 0

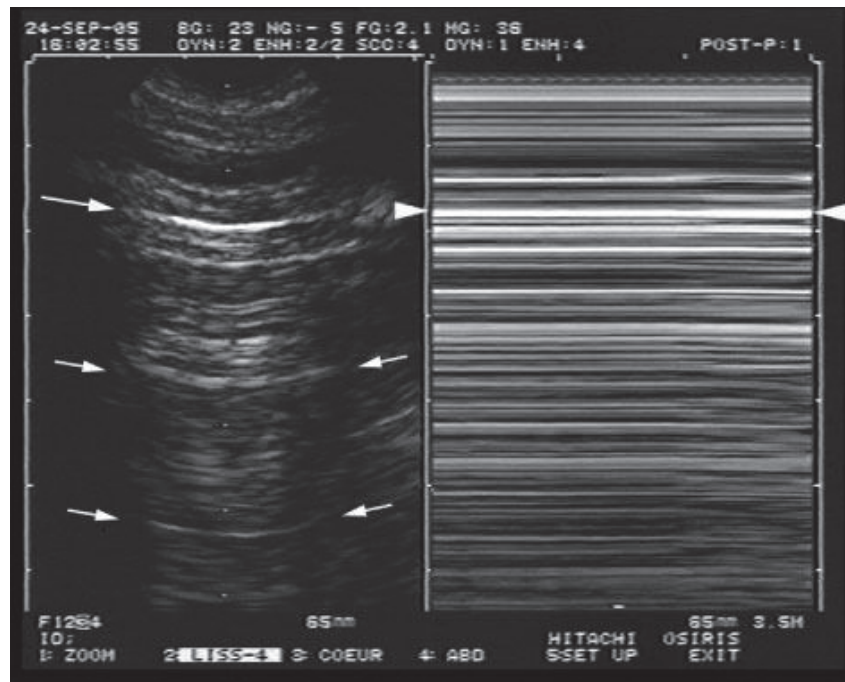
THI

Pneumothorax

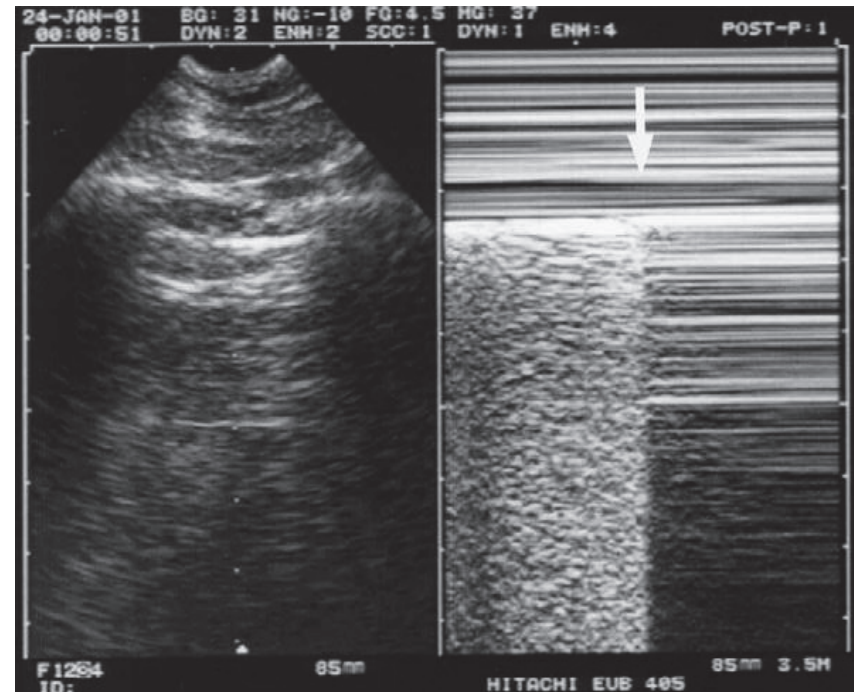
Se: 94%, Sp: 95%



Abolition du glissement pleural
VPP 100%

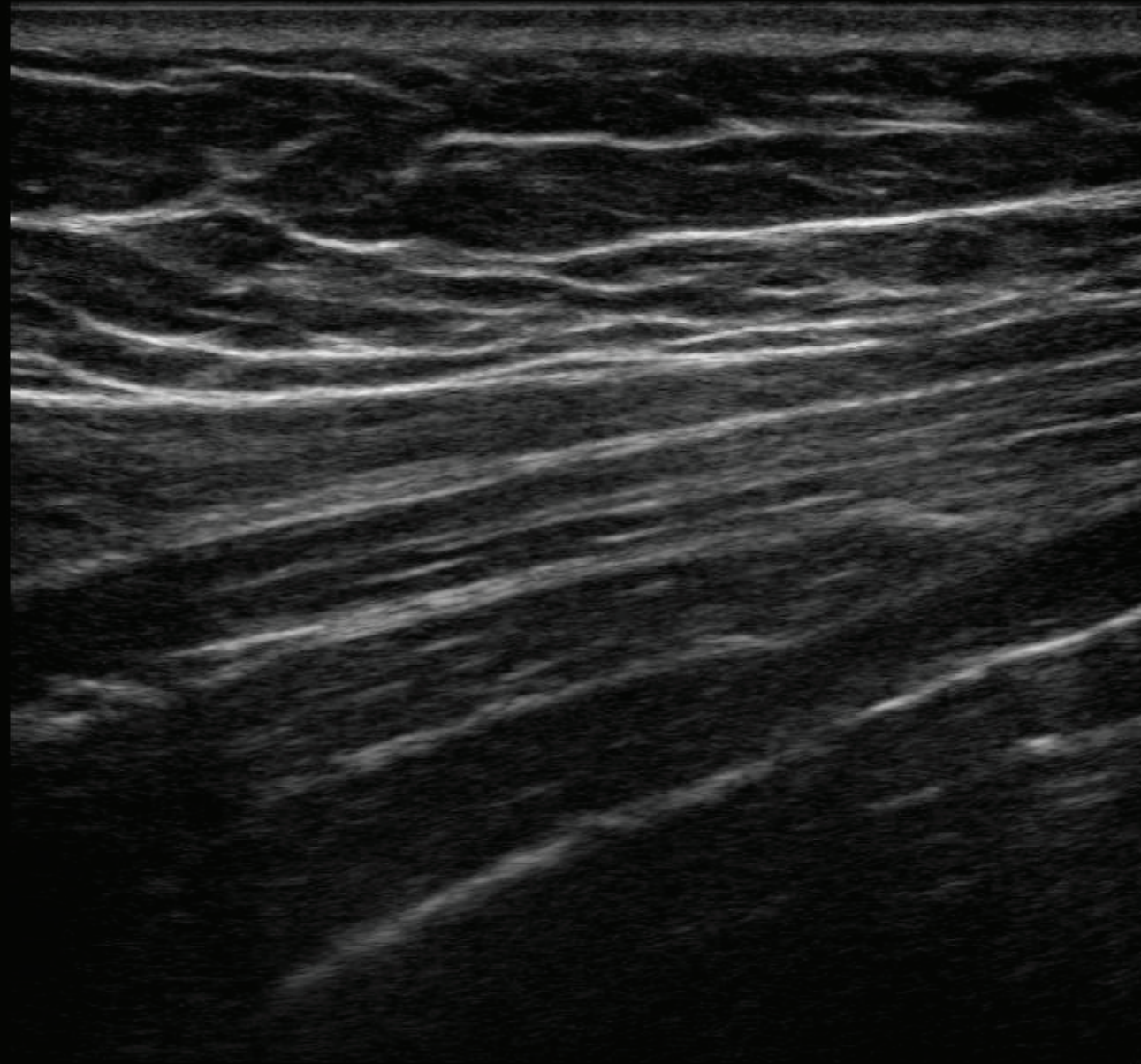


Point poumon
Spécifique à 100%



Lichtenstein D, Mezière G, Lascols N, Biderman P, Courret JP, Gepner A, et al.
Ultrasound diagnosis of occult pneumothorax.
Critical Care Med 2005;33:1231–8.

14 Jan 2014 / 12:38

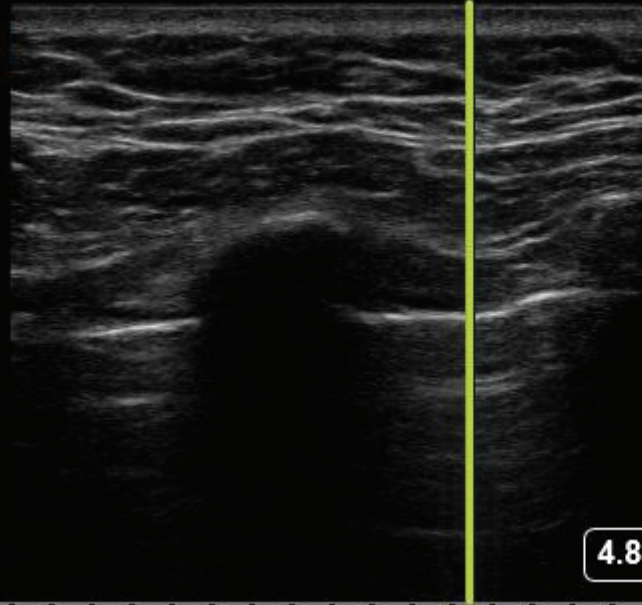


4.8 cm


SonoSite
HFL50xp/15-6 Neuro.
IM: 0.7 ITM: 0.2

2D: G: 50
PD: 0
MB

14 Jan 2014 / 12:39

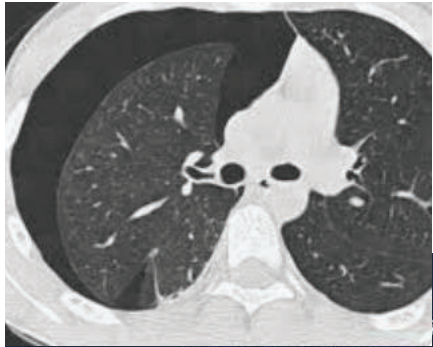

4.8 cm



SonoSite
HFL50xp/15-6 Neuro.
IM: 0.9 ITM: 0.2

M: G: 50 2D: G: 50
PD: 0



742

CHU PURPAN

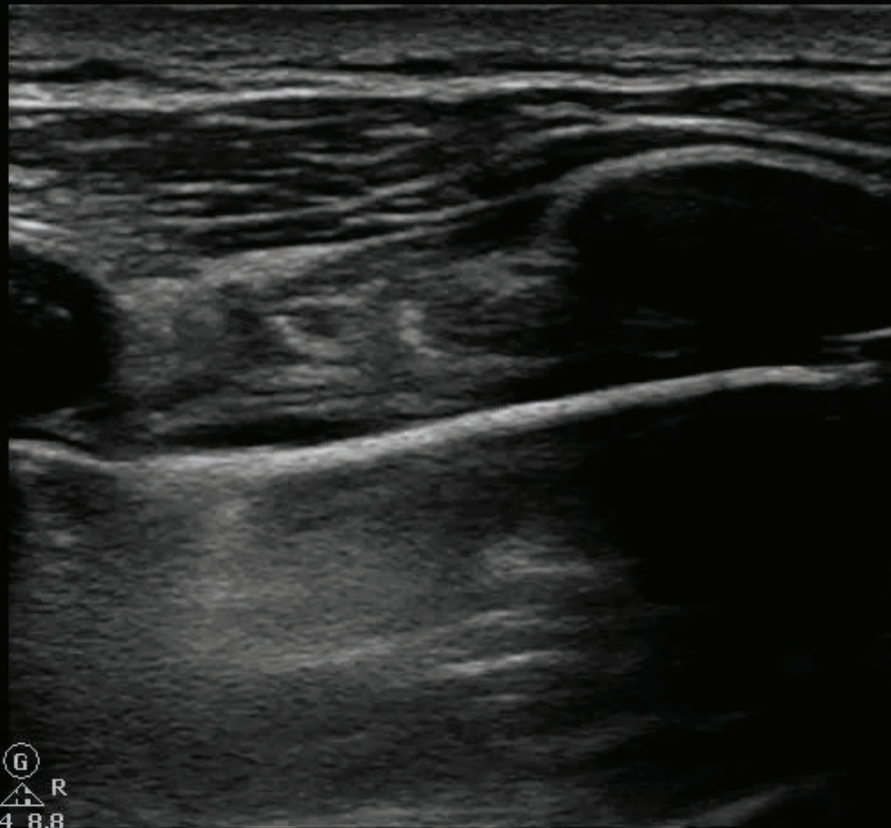
IM 1,1 02/09/2015

ITm 0,2 15:48:04

VEINE optin
L12-3
42Hz
3,5cm

P

2D
HGén
Gn 34
C 41
3 / 3 / 2



G
P R
4,4 8,8

3,5cm



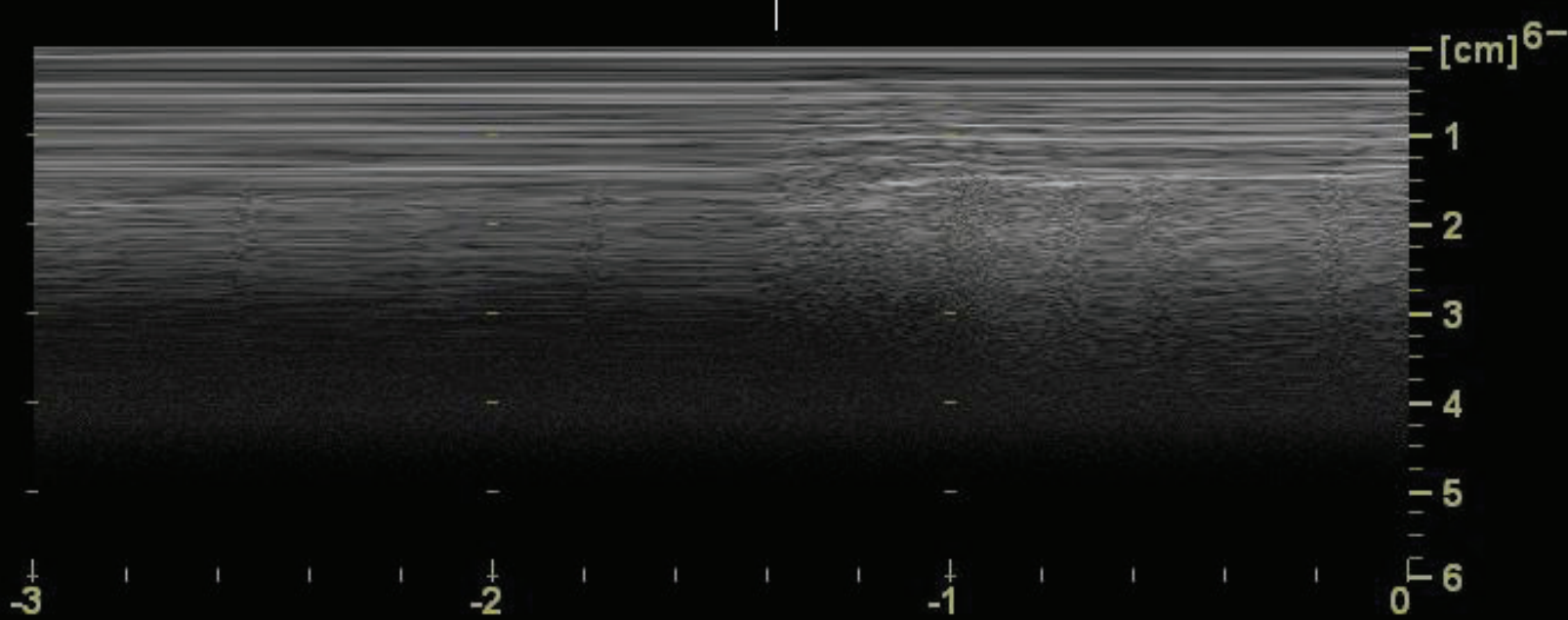
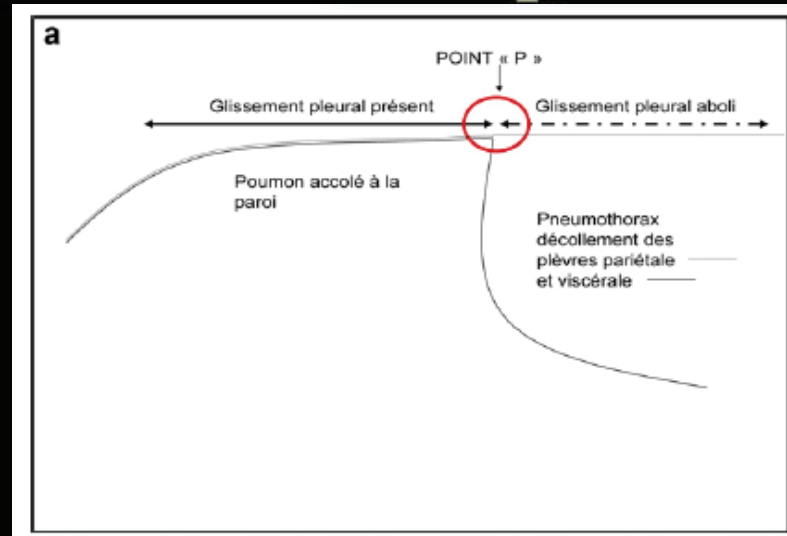
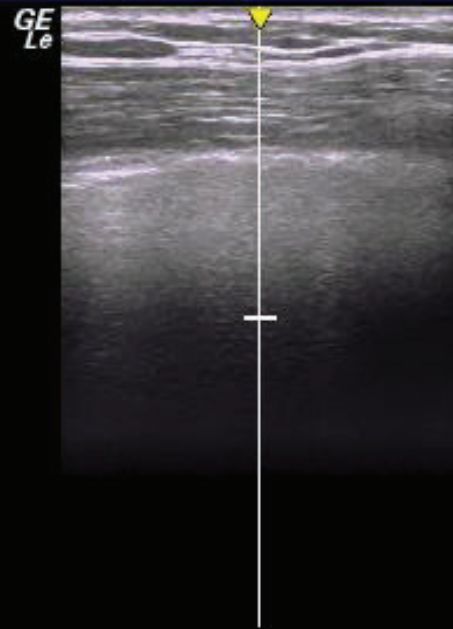
chu purpan
05/04/13 15:25:08

ADM

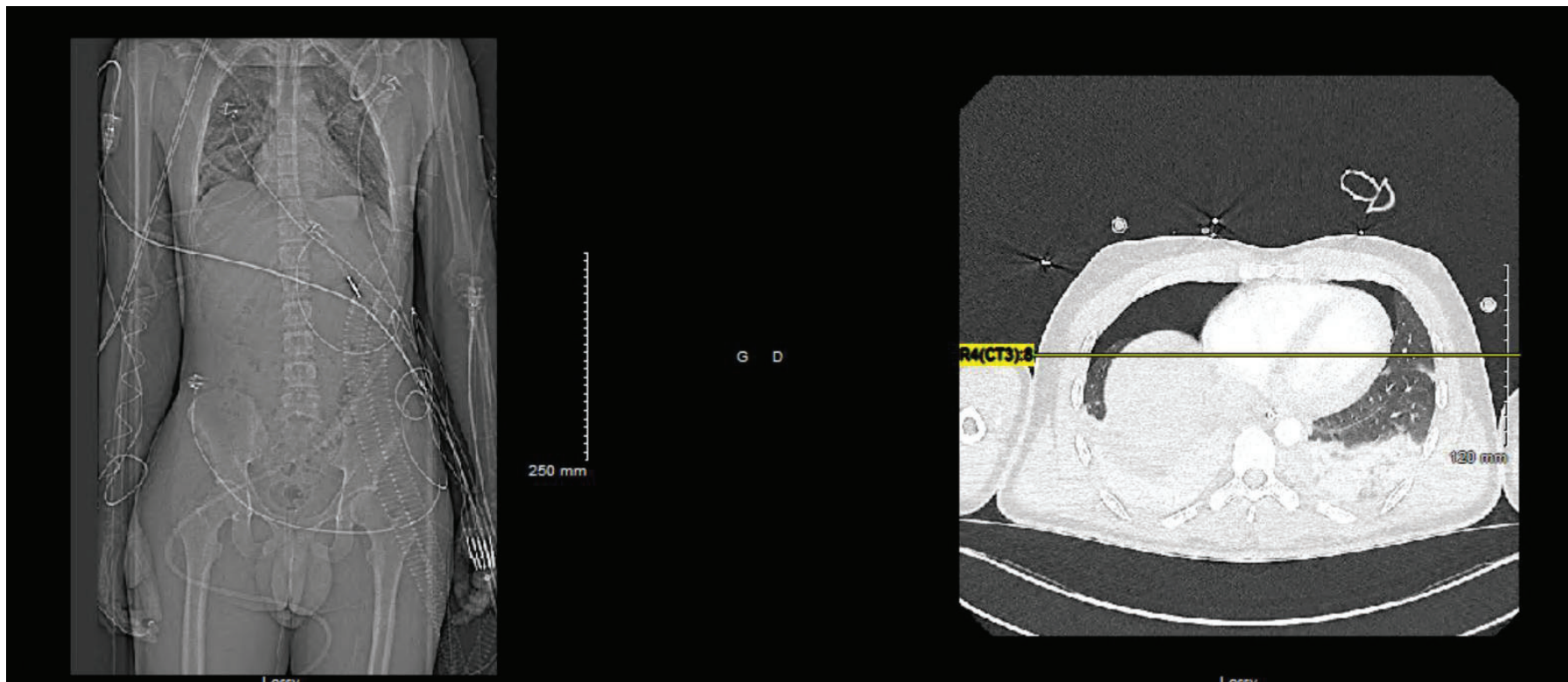
XXXX,
XXXX

MI 0.33 TIs 0.7
--:--:--

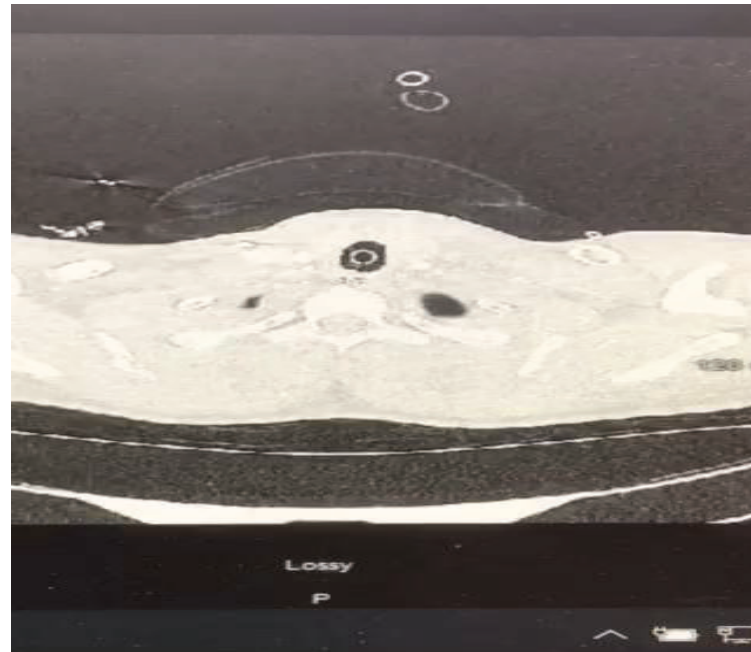
12L-RS
Parties Molles



Mr D, 19 ans chute de 7 m, traumatisme crânien sévère, traumatisme thoracique et fracture ouverte du calcaneum



Faut il le
drainer?



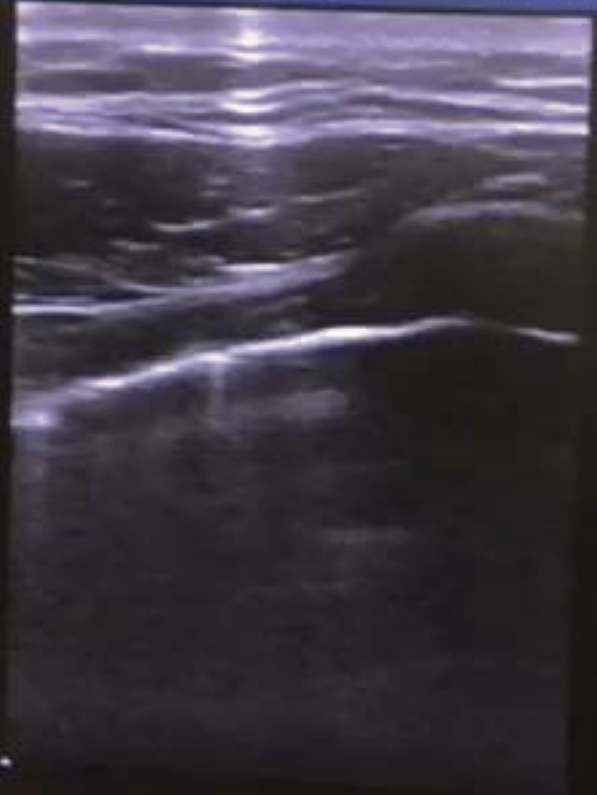
bs 22-09-30-220353

CHU PURPAN

ITm 0,1 11:57:07

OPHTALMIQ
L12-3
3-4Hz
5,0cm

20
HGén
Gn 100
C 50
3/3/2

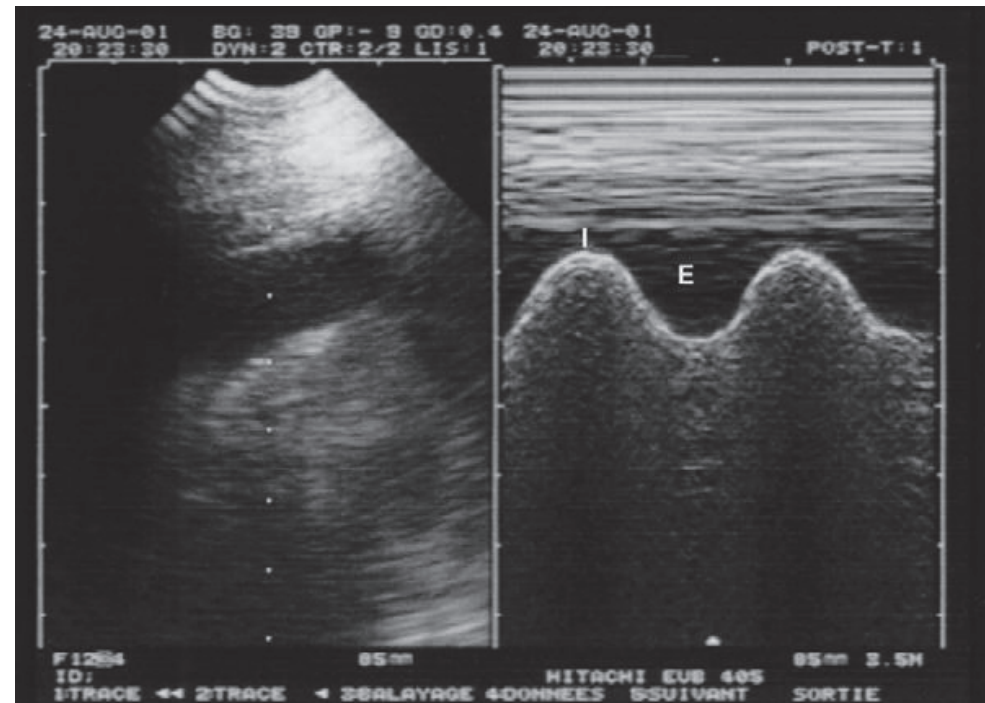
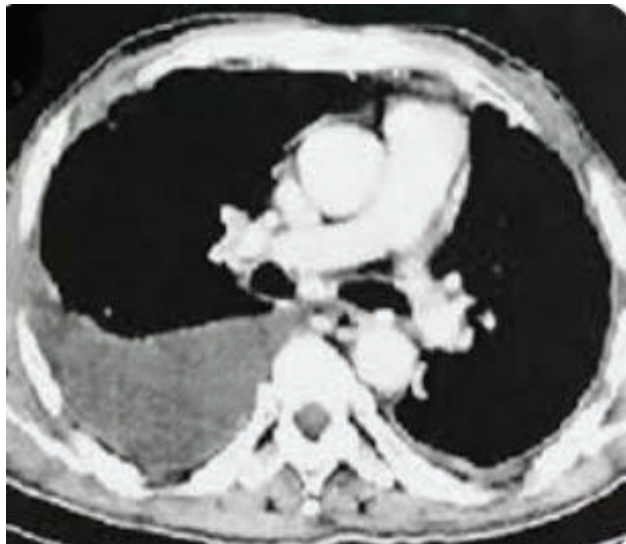
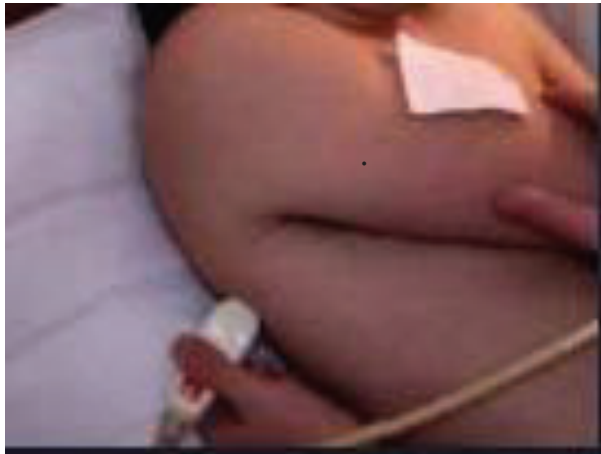


©
P R
4.1 8.8

Épanchement pleural

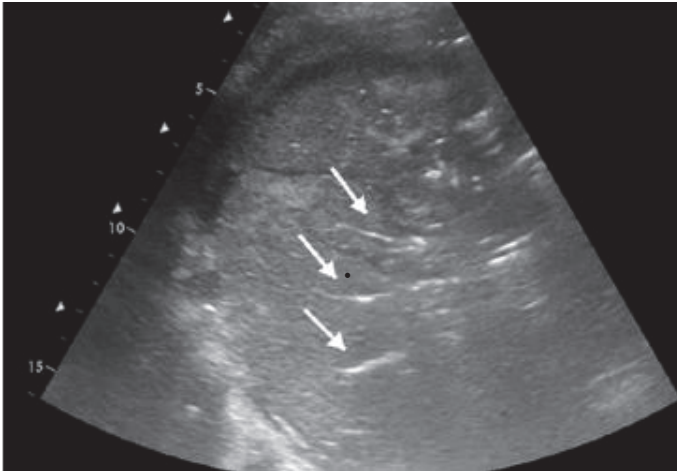
Se:94%, Sp:97%

Lichtenstein D, Mezière
Intensive Care Med 1999;25:955-8



Consolidation alvéolaire

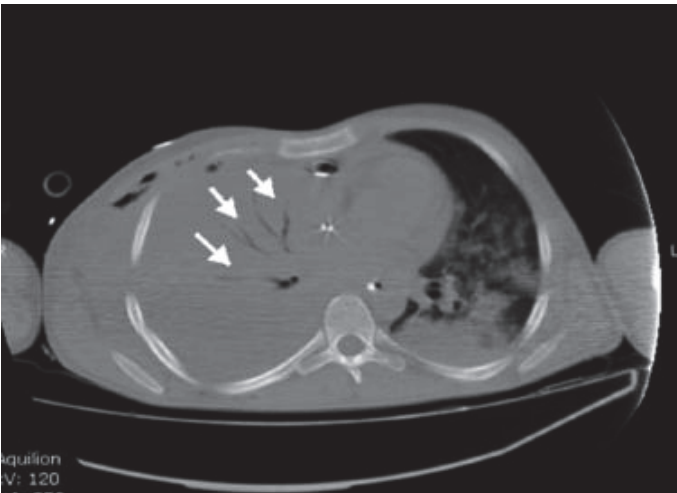
Se:90%, Sp:98%



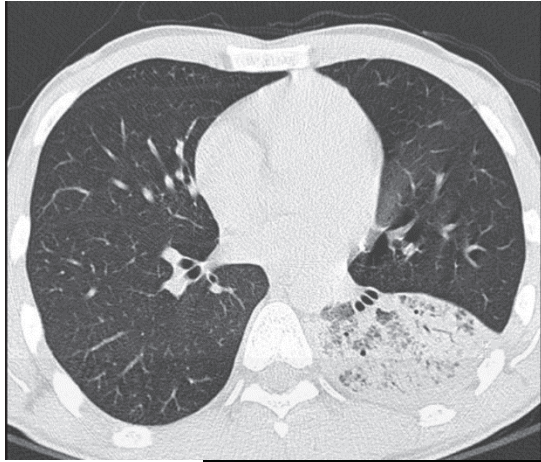
- signe du poumon tissulaire:
tissu solide avec échogénicité
tissulaire (hépatisation)

- + spécifique que la RT

- Lignes hyperéchogène
bronchogramme aérique



*Lichtenstein D, .
Ultrasound diagnosis of alveolar consolidation
in the critically ill.
Intensive Care Med 2004;30:276—81.*



2012Sep27 15:48

Crd
P21

95%

IM
1,0

ITM
0,7

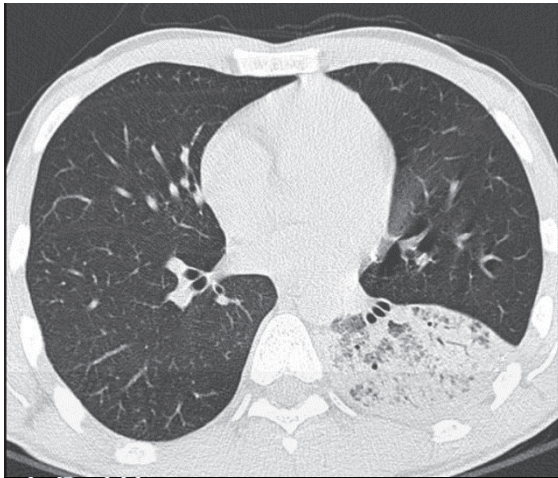A

B

13°

Gén 0 Secteur MB Non TH1 Actif Page 1/3

This is a B-mode echocardiogram showing the heart's internal structure. A green dot is visible in the upper part of the image. The interface includes a date and time stamp, patient information (Crd P21), a battery level indicator (95%), and various technical parameters (IM 1,0, ITM 0,7). There are also checkboxes for 'A' and 'B' views, a degree indicator (13°), and a bottom status bar with icons and text: 'Gén 0 Secteur MB Non TH1 Actif Page 1/3'.

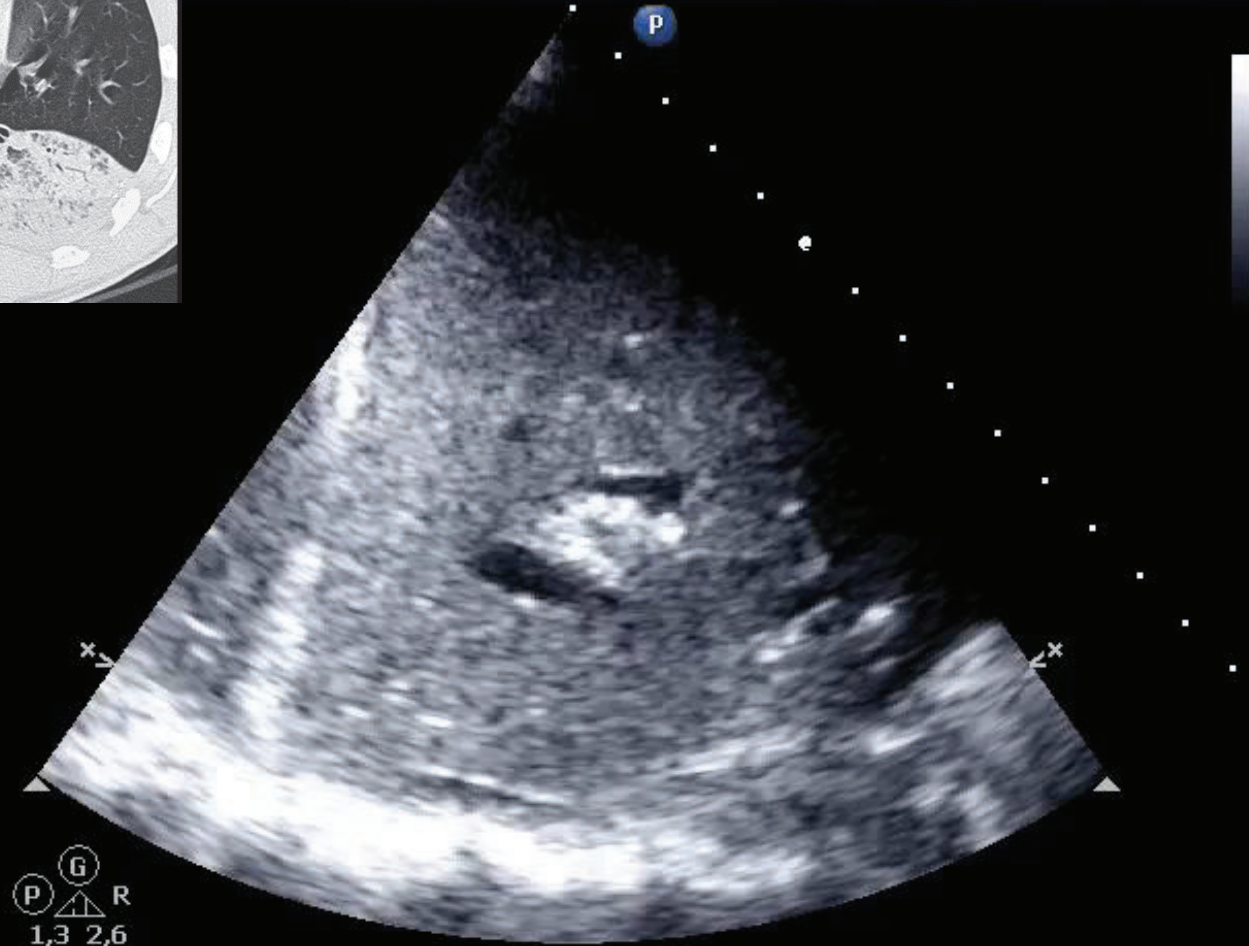


Gn 10
C 53
3/2/0
75 mm/s

CHU PURPAN

IM 0,6 25/08/2015

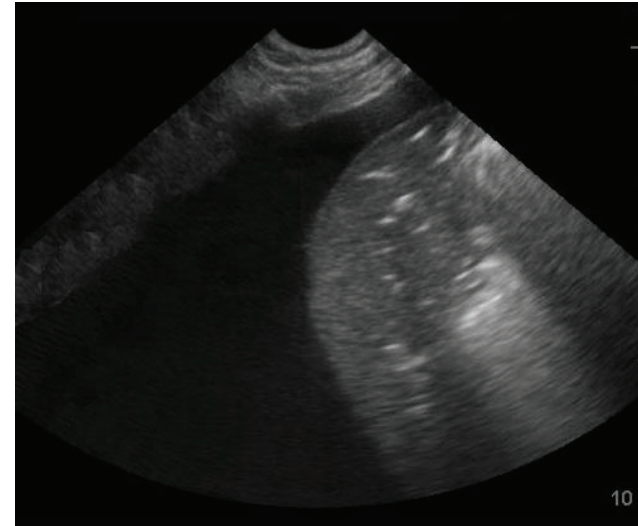
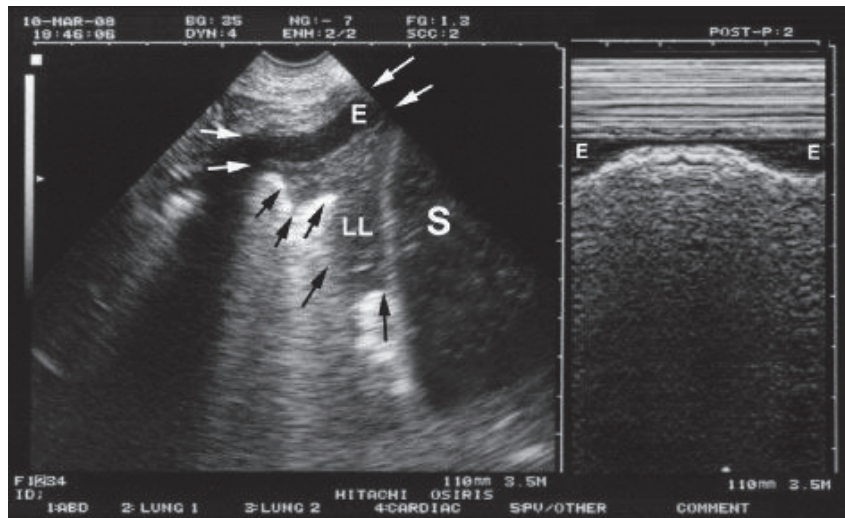
ITm 0,2 12:39:11



G
P R
1,3 2,6

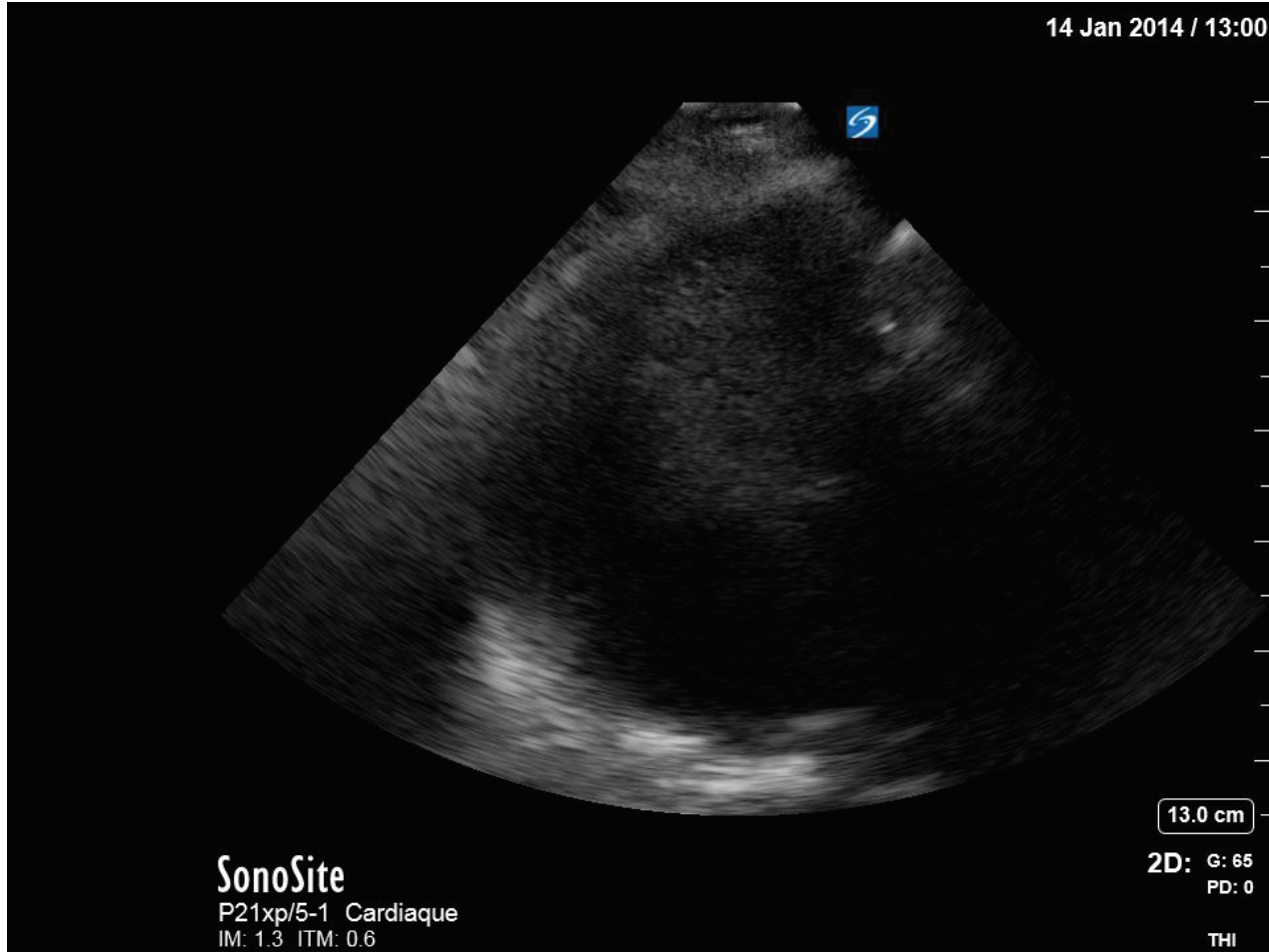
PLAPS

postero lateral alveolar and pleural syndrome



Zone 3, condensation pulmonaire et épanchement pleural
Flèches noires = bronchogramme aérique

14 Jan 2014 / 13:00

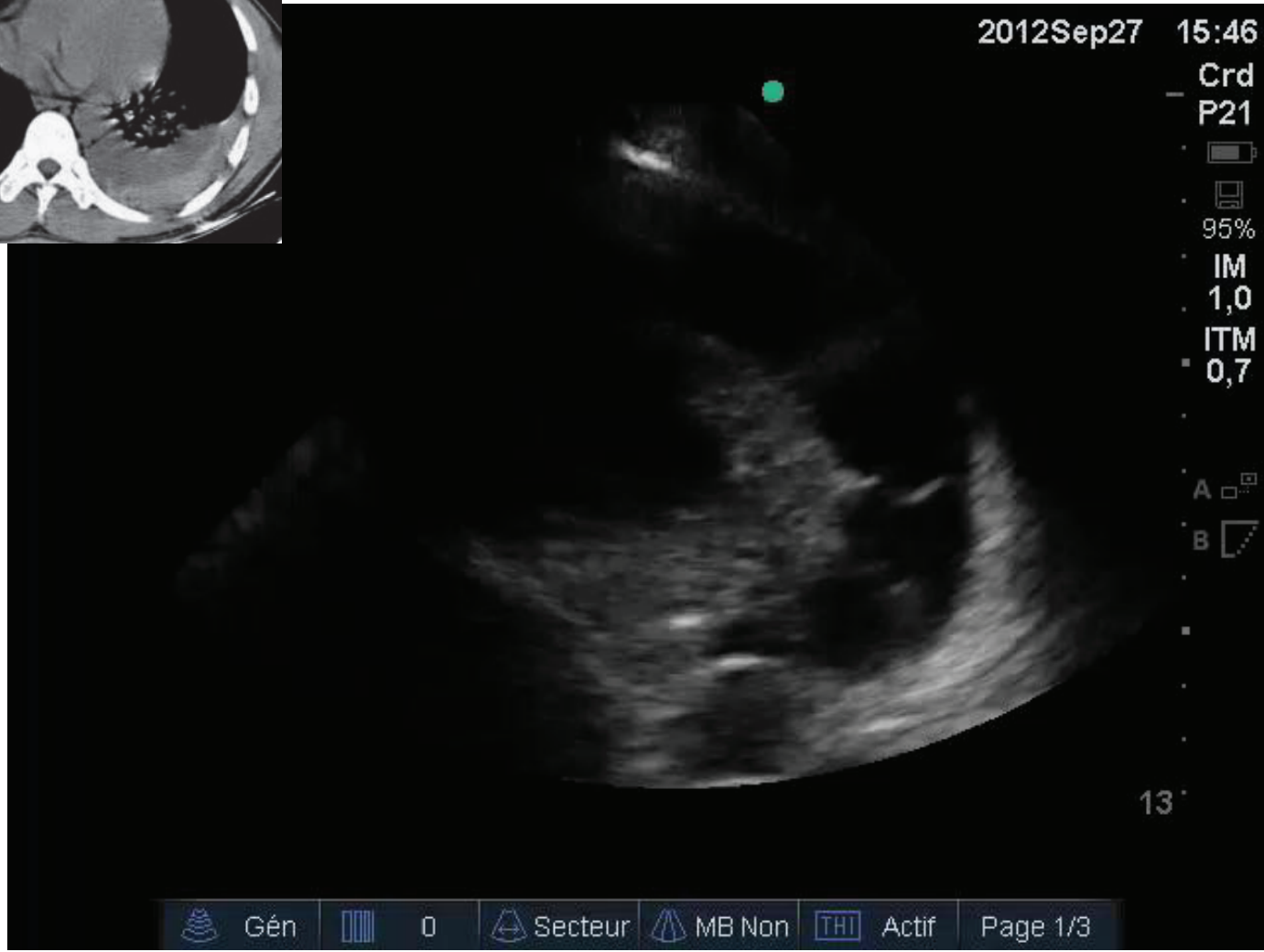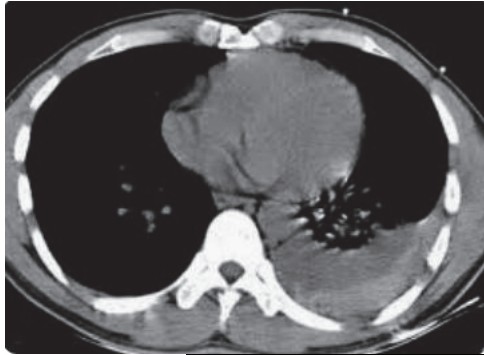


SonoSite
P21xp/5-1 Cardiaque
IM: 1.3 ITM: 0.6

13.0 cm

2D: G: 65
PD: 0

THI



2012Sep27 15:46

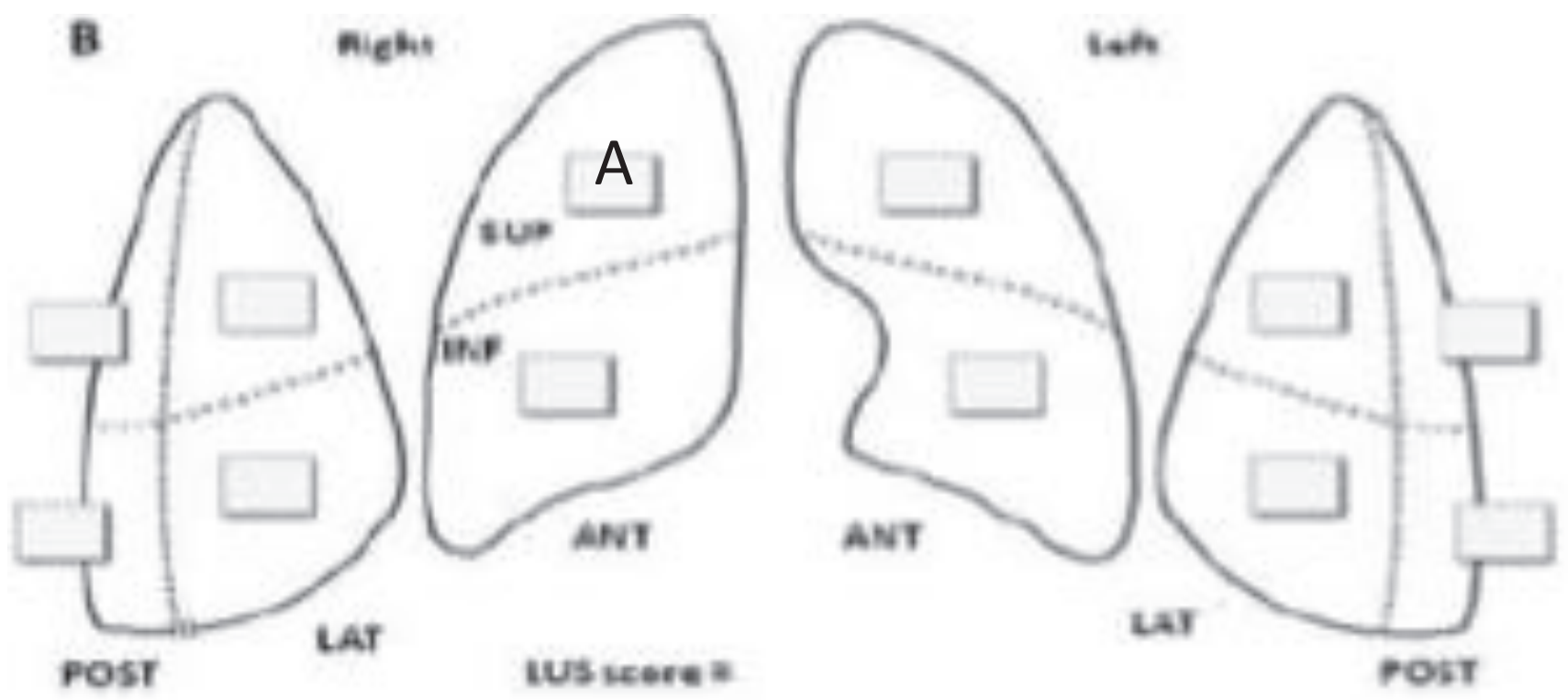
Crd
P21

95%


IM
1,0
ITM
0,7

A
B

13



Pattern: Score 0



LUS 0
LIGNE A

B1-pattern: Score 1



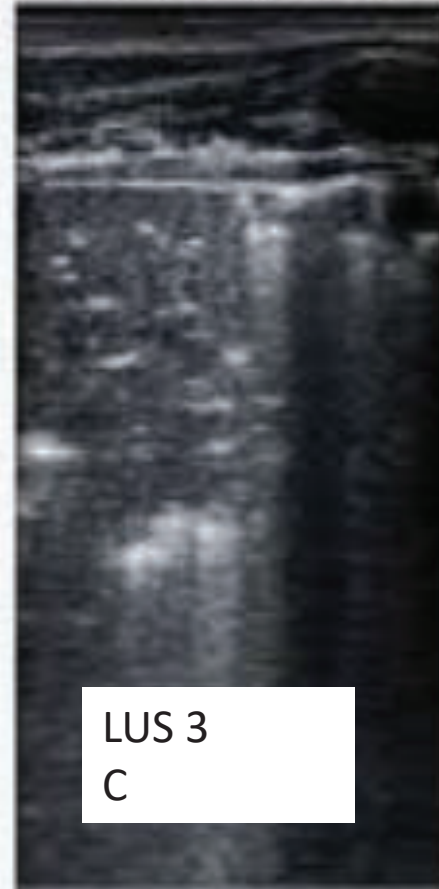
LUS 1
LIGNE B1

B2-pattern: Score 2



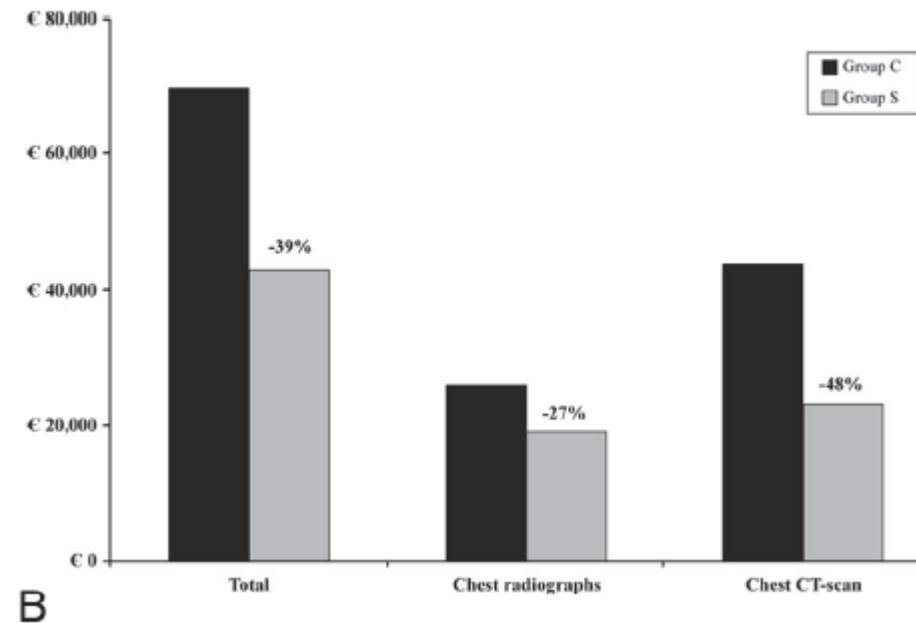
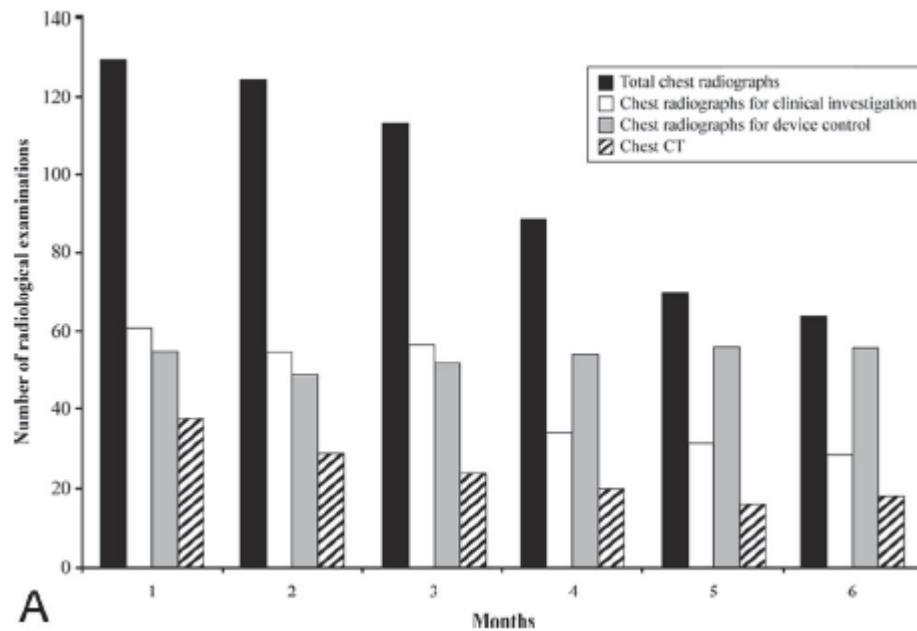
LUS 2
LIGNE B2

C-pattern: Score 3



LUS 3
C

Étude médico économique



6mois,376 patients

Conclusion: Routine use of LUS in the ICU setting can be associated with a reduction of the number of chest radiographs and CT scans performed.
(Balik M, Anesth Analg 2010;111:687-92)

Applications cliniques

- Diagnostique d'une détresse respiratoire
- Atélectasie ou pneumopathie ?
- Évaluation quantitative d'un épanchement pleural
- Recrutement alvéolaire dans sdra
- Recrutement alvéolaire et DV
- Efficacité d'un traitement ATB PAVM
- Diagnostic précoce PAVM

Diagnostic d'une DRA

Relevance of Lung Ultrasound in the Diagnosis of Acute Respiratory Failure *

Daniel A. Lichtenstein and Gilbert A. Mezière

Chest 2008; 134; 117-125; Prepublished online April 10, 2008;
DOI 10.1378/chest.07-2800



- Étude observationnelle
- Patients consécutifs hospitalisés pour DRA, 1 centre, 304 patients, 4 ans
- Comparaison entre écho pulm initial et diagnostique final retenu (CR de sortie)
- 3 items:
 - Artefacts (ligne A, ligne B)
 - Glissement pleural
 - Condensation pulm +/- épanchement pleural

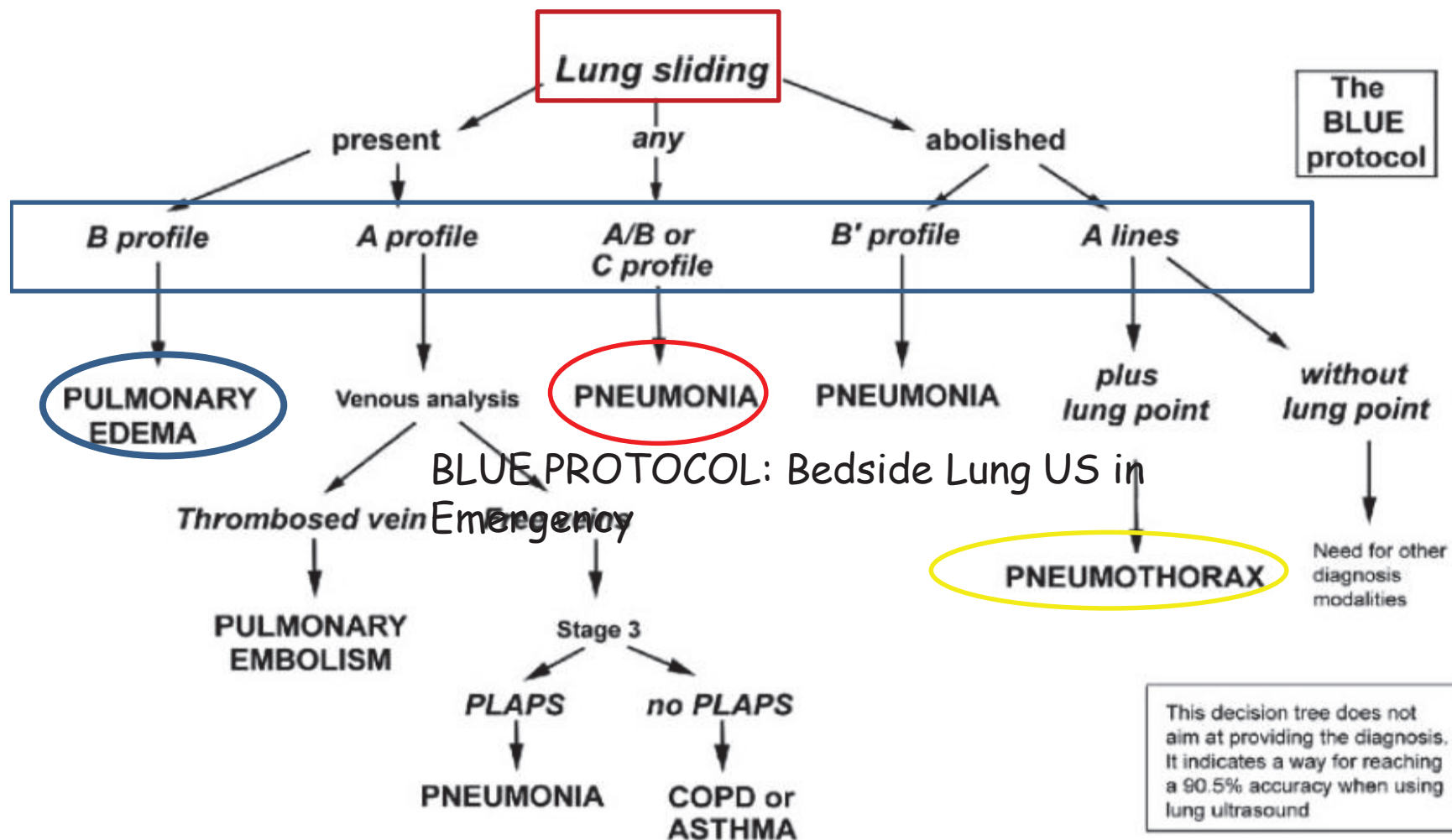



FIGURE 7. A decision tree utilizing lung ultrasonography to guide diagnosis of severe dyspnea.



CHEST

Original Research

CRITICAL CARE

Usefulness of Cardiothoracic Chest Ultrasound in the Management of Acute Respiratory Failure in Critical Care Practice

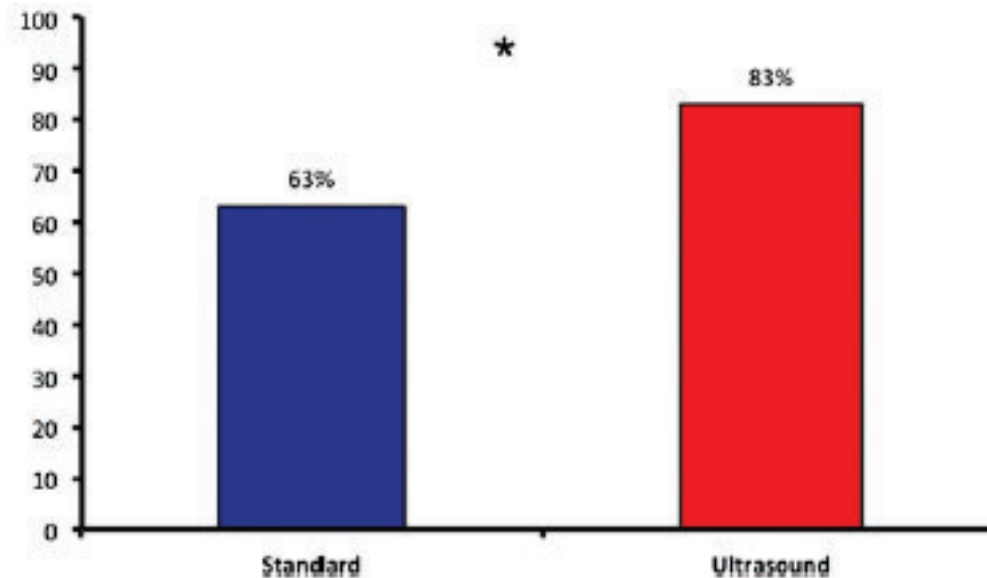
*Stein Silva, MD, PhD; Caroline Biendel, MD; Jean Ruiz, MD; Michel Olivier, MD;
Benoit Bataille, MD; Thomas Geeraerts, MD, PhD; Arnaud Mari, MD;
Beatrice Riu, MD; Olivier Fourcade, MD, PhD; and Michele Genestal, MD*

Chest. 2013;144(3):859-865. doi:10.1378/chest.13-0167



Usefulness of Cardiothoracic Chest Ultrasound in the Management of Acute Respiratory Failure in Critical Care Practice

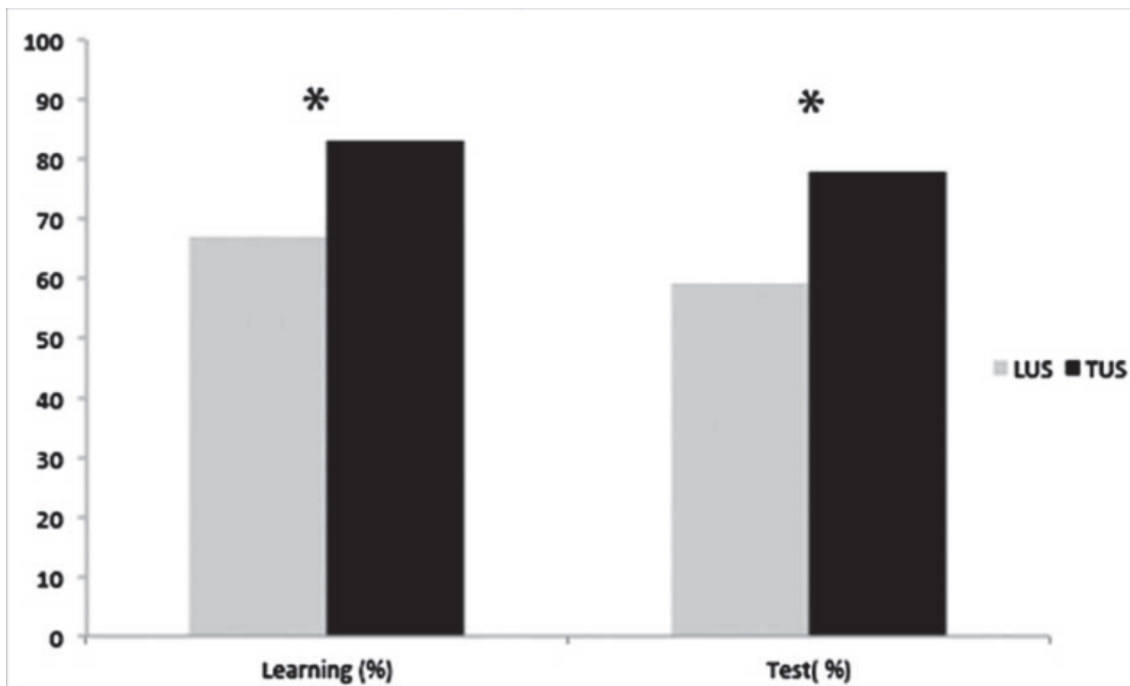
Stein Silva, MD, PhD; Caroline Biendel, MD; Jean Ruiz, MD; Michel Olivier, MD; Benoit Bataille, MD; Thomas Geeraerts, MD, PhD; Arnaud Mari, MD; Beatrice Riu, MD; Olivier Fourcade, MD, PhD; and Michele Genestal, MD



15] FIGURE 1. Comparative diagnostic accuracy. Each diagnostic approach (standard and ultrasound) was compared against the final
16] diagnosis determined by a panel of experts ($P < .05$).

Integrated Use of Bedside Lung Ultrasound and Echocardiography in Acute Respiratory Failure A Prospective Observational Study in ICU

Benoit Bataille, MD; Beatrice Riu, MD; Fabrice Ferre, MD; Pierre Etienne Moussot, MD; Arnaud Mari, MD; Elodie Brunel, MD; Jean Ruiz, MD; Michel Mora, MD; Olivier Fourcade, MD, PhD; Michele Genestal, MD; and Stein Silva, MD, PhD



évaluation quantitative d'un épanchement pleural

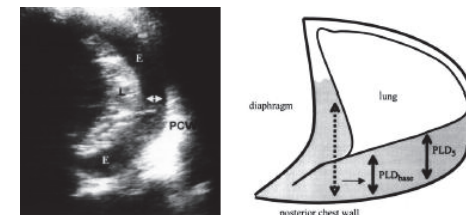
- **Vignon P, Chastagner C, Berkane V, et al.** Quantitative assessment of pleural effusion in critically ill patients by means of ultrasonography. Crit Care Med 2005; **33**: 1757-1763.

Vol > 800ml si d > 45mm, Se=94%, Sp=100%

- **Balik M, Plasil P, Waldauf P, et al.** Ultrasound estimation of volume of pleural fluid in mechanically ventilated patients. Intensive Care Med 2006; **32**: 318-321.

$V \text{ (ml)} = 20 \times \text{Sep (mm)},$

- **Roch A, Bojan M, Michelet P, et al.** Usefulness of Ultrasonography in predicting pleural effusions > 500 mL in patients receiving Mechanical Ventilation. Chest 2005; **127**: 224-232.



Faut il réaliser un **écho guidage** pour la pose d'un drain

Reducing Iatrogenic Pneumothoraces: Using Real-Time Ultrasound Guidance for Pleural Procedures

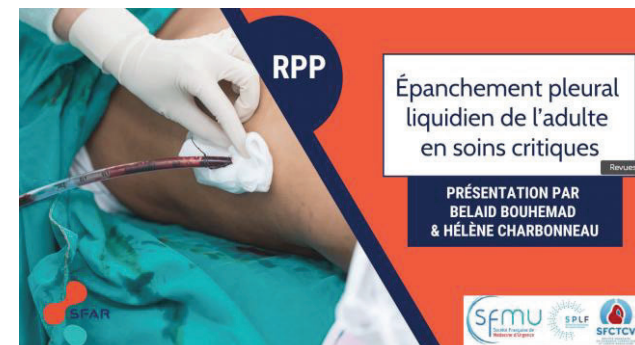Helgeson, Scott A. MD¹; Fritz, Ashley V. DO²; Tatari, Mehmet M. MD¹; Daniels, Craig E. MD³; Diaz-Gomez, Jose L. MD^{1,2}

[Author Information](#) 

Critical Care Medicine: July 2019 - Volume 47 - Issue 7 - p 903-909

TABLE 3. Primary and Secondary Endpoints by Ultrasound Marked or Guided Procedures

Endpoints	Ultrasound Marked, <i>n</i> = 203, <i>n</i> (%)	Ultrasound Guided, <i>n</i> = 159, <i>n</i> (%)	OR (95% CI)	<i>p</i>
Primary				
Pneumothorax rate	9 (5.01)	1 (0.70)	0.14 (0.02–0.88)	0.03



Combined Thoracic Ultrasound Assessment during a Successful Weaning Trial Predicts Postextubation Distress

Stein Silva, M.D., Ph.D., Dalinda Ait Aissa, M.D., Pierre Cocquet, M.D., Lucille Hoarau, M.D., Jean Ruiz, M.D., Fabrice Ferre, M.D., David Rousset, M.D., Michel Mora, M.D., Arnaud Mari, M.D., Olivier Fourcade, M.D., Ph.D., Béatrice Riu, M.D., Samir Jaber, M.D., Ph.D., Benoît Bataille, M.D.

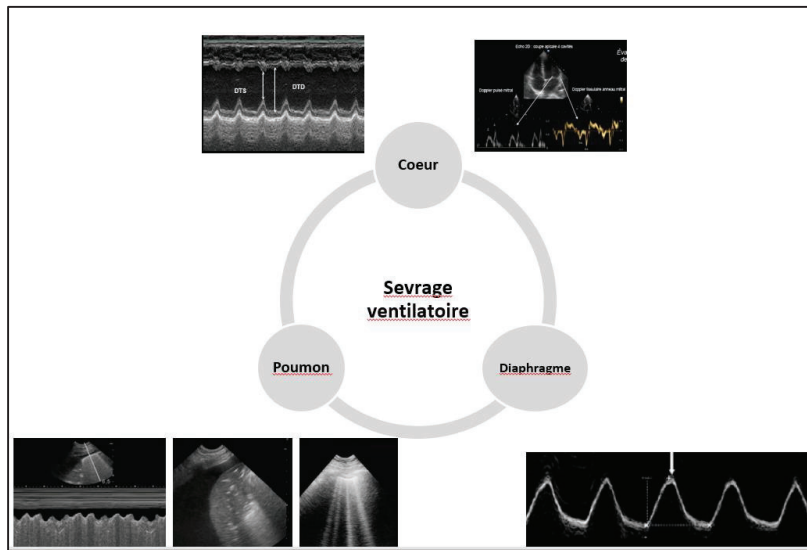
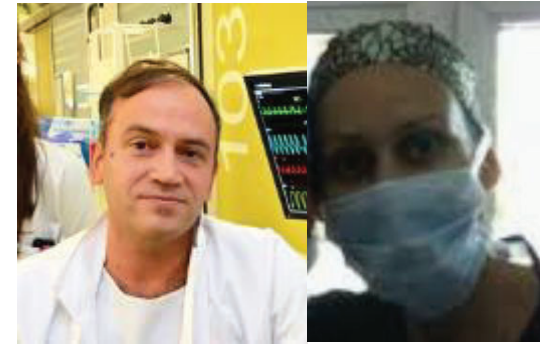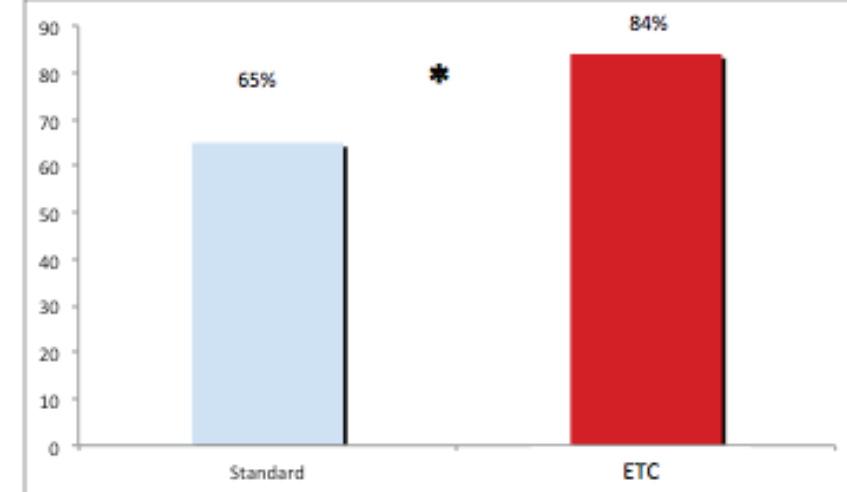


Figure 5: Précision diagnostique des causes de l'échec du sevrage ventilatoire



Ultrasound findings of lung ultrasonography in COVID-19: A systematic review

Jaime Gil-Rodríguez^{a,*}, Javier Pérez de Rojas^b, Pablo Aranda-Laserna^a, Alberto Benavente-Fernández^a, Michel Martos-Ruiz^a, José-Antonio Peregrina-Rivas^c, Emilio Guirao-Arrabal^c

^a Internal Medicine Unit, San Cecilio University Hospital, Avenida del Conocimiento s/n, 18016 Granada, Spain

^b Preventive Medicine and Public Health Unit, San Cecilio University Hospital, Avenida del Conocimiento s/n, 18016 Granada, Spain

^c Infectious Diseases Unit, San Cecilio University Hospital, Avenida del Conocimiento s/n, 18016 Granada, Spain



► Crit Care Explor. 2022 Jun 8;4(6):e0719. doi: [10.1097/CCE.0000000000000719](https://doi.org/10.1097/CCE.0000000000000719)



Lung Ultrasound to Assist ICU Admission Decision-Making Process of COVID-19 Patients With Acute Respiratory Failure

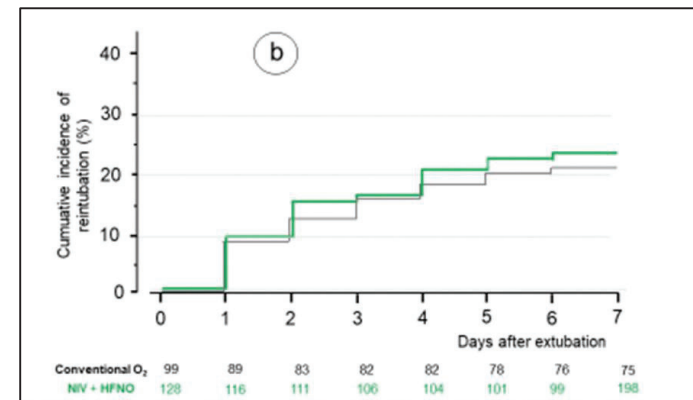
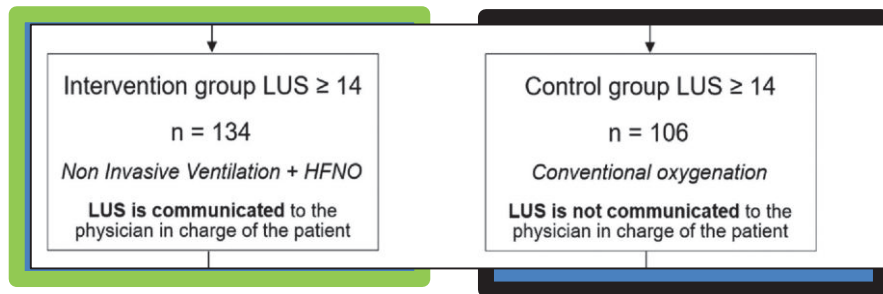
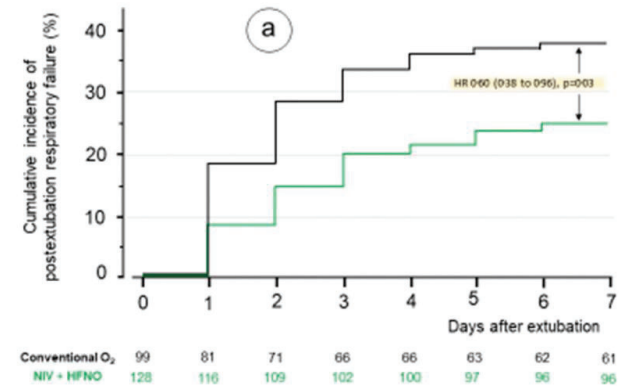
[Amazigh Aguersif](#)¹, [Benjamine Sarton](#)^{1,2}, [Sihem Bouharaoua](#)¹, [Lucien Gaillard](#)¹, [Denis Standarovski](#)³, [Orphée Faucoz](#)³, [Guillaume Martin Blondel](#)⁴, [Hatem Khallel](#)⁵, [Claire Thalamas](#)⁶, [Agnes Sommet](#)⁶, [Béatrice Riu](#)², [Eric Morand](#)³, [Benoit Bataille](#)⁷, [Stein Silva](#)^{1,2},

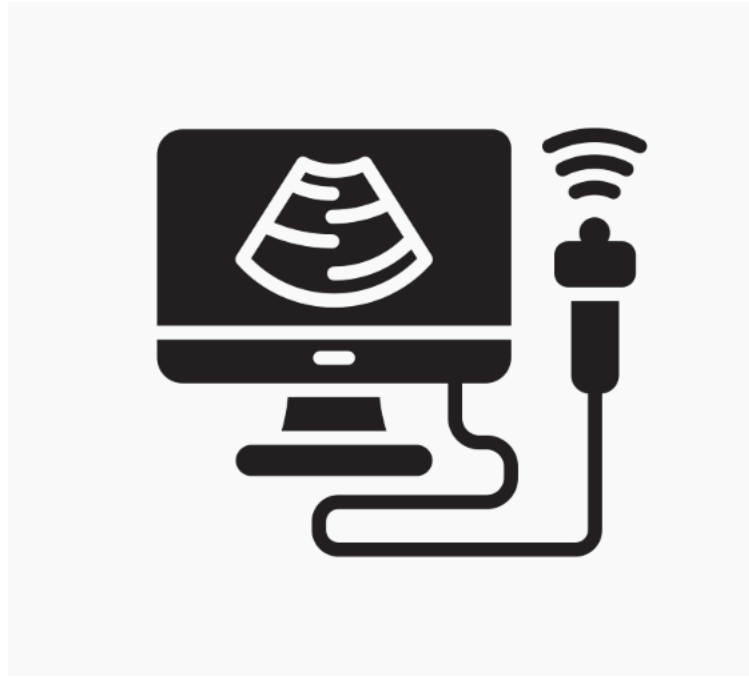
RESEARCH

Open Access

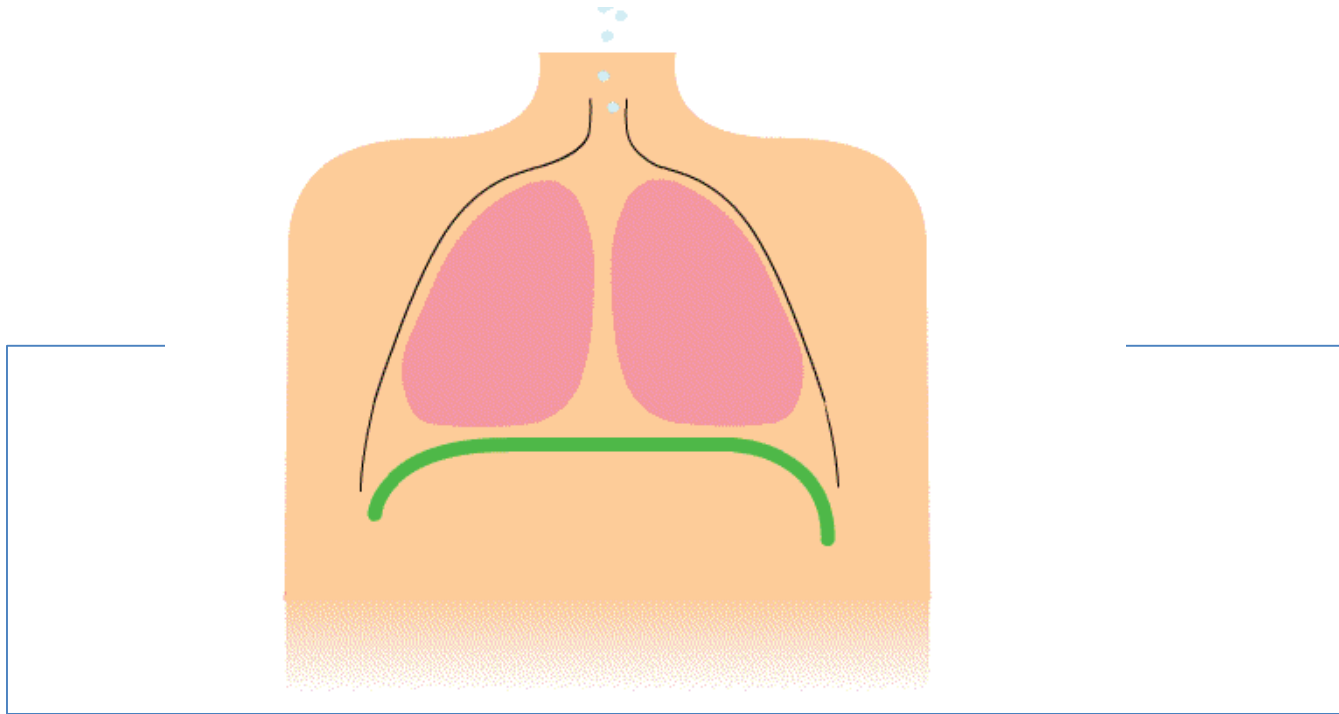
Weaning of non COPD patients at high-risk of extubation failure assessed by lung ultrasound: the WIN IN WEAN multicentre randomised controlled trial

Jean-Jacques Rouby^{1*}, Sébastien Perbet², Jean-Pierre Quenot³, Mao Zhang⁴, Pascal Andreu³, Mona Assefi¹,



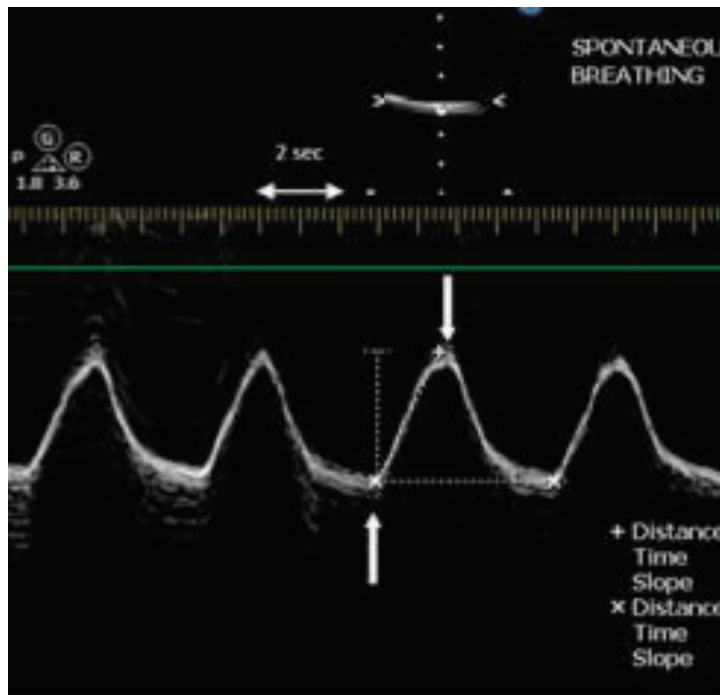


Le diaphragme

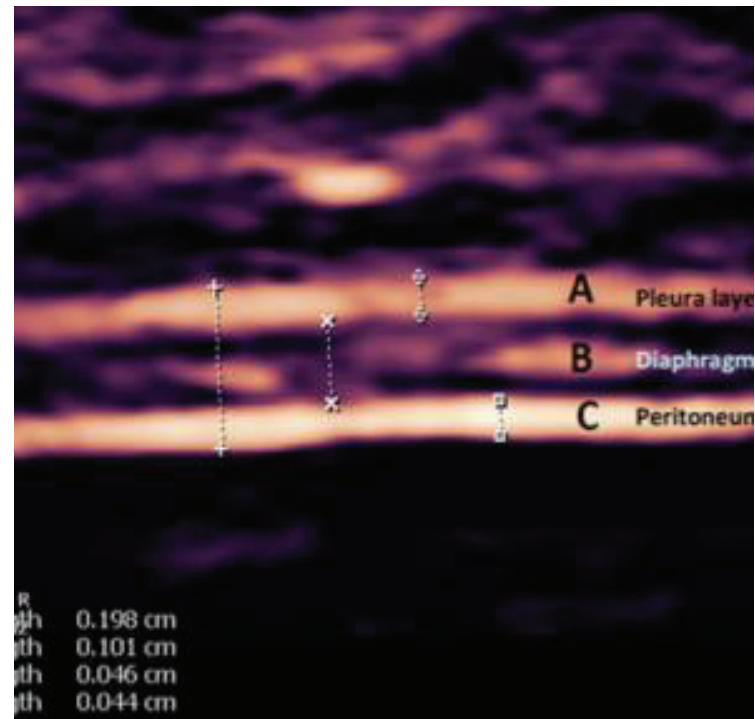


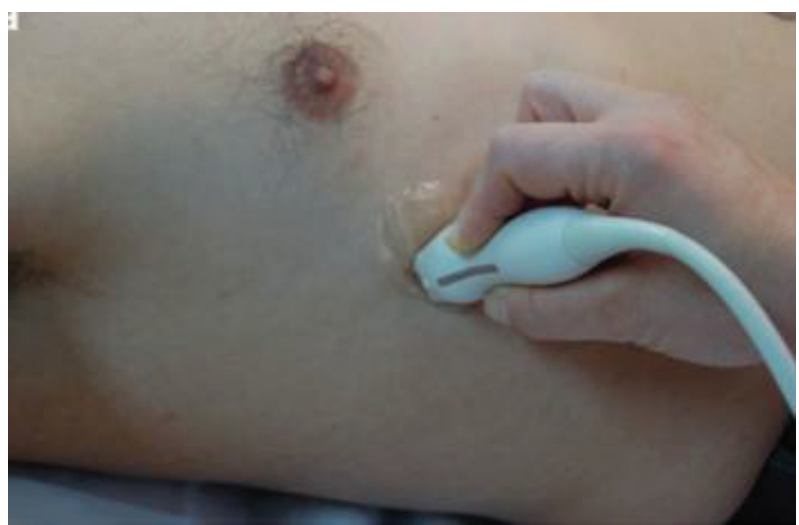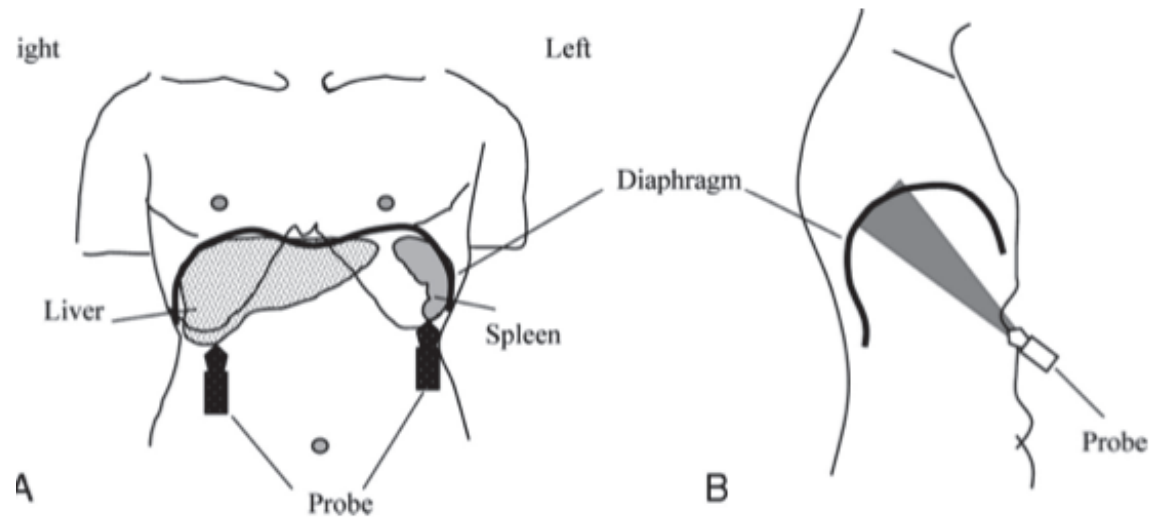
2 techniques US

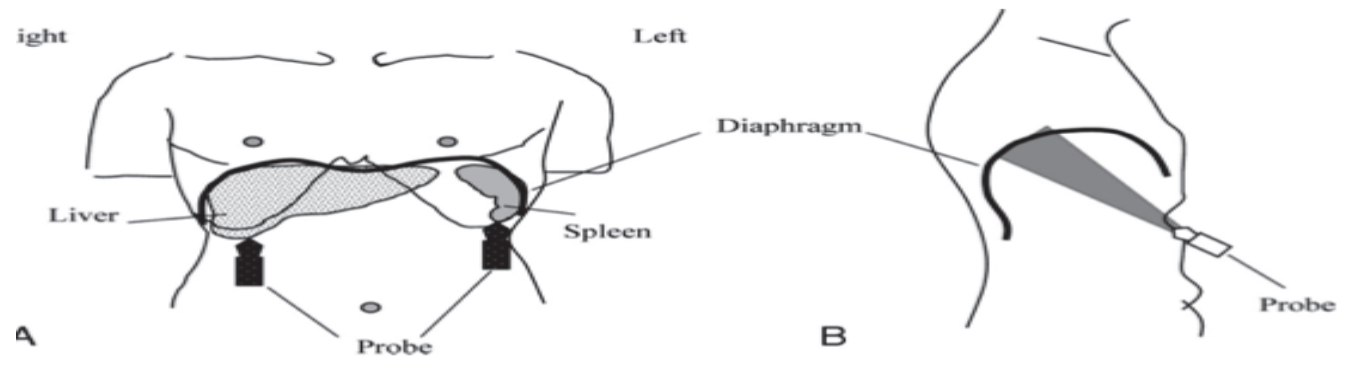
Excursion diaphragmatique



Fraction de raccourcissement

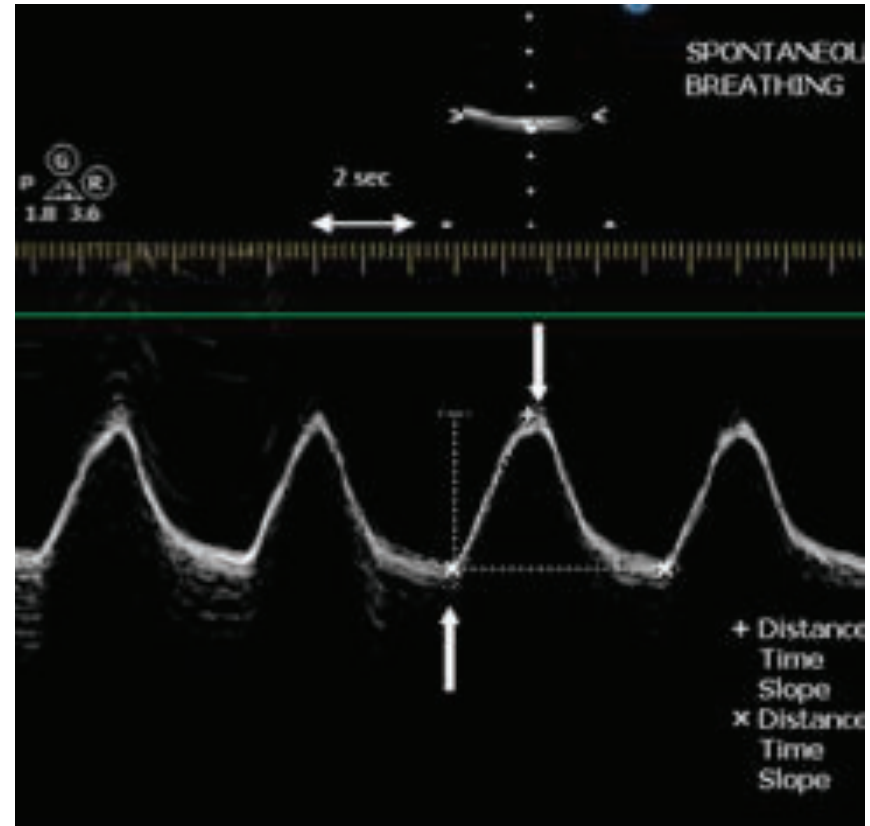
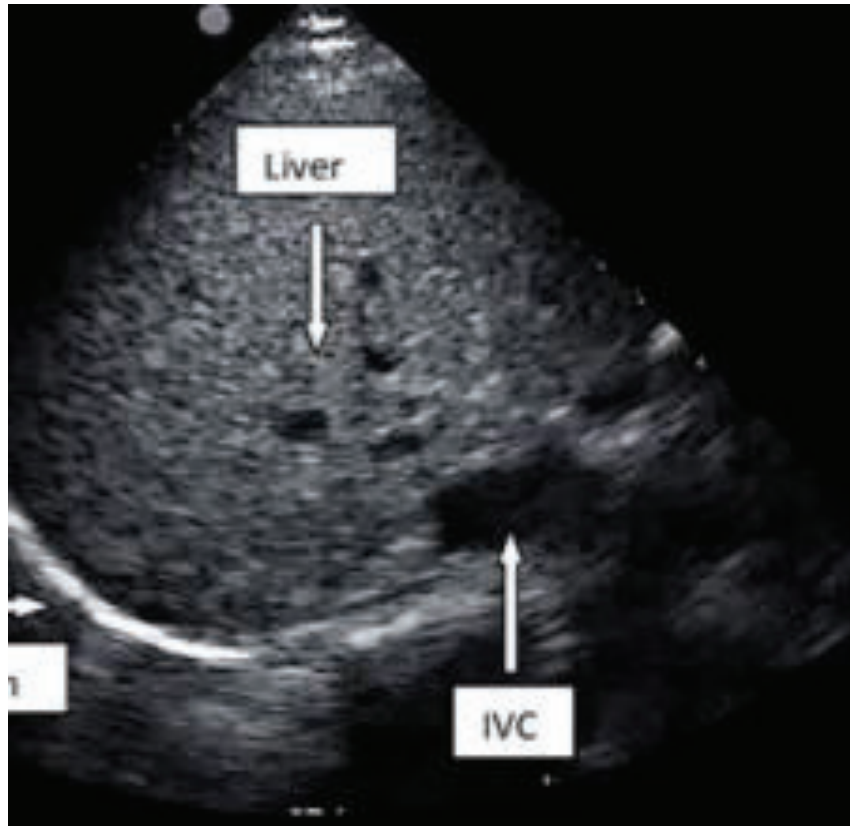


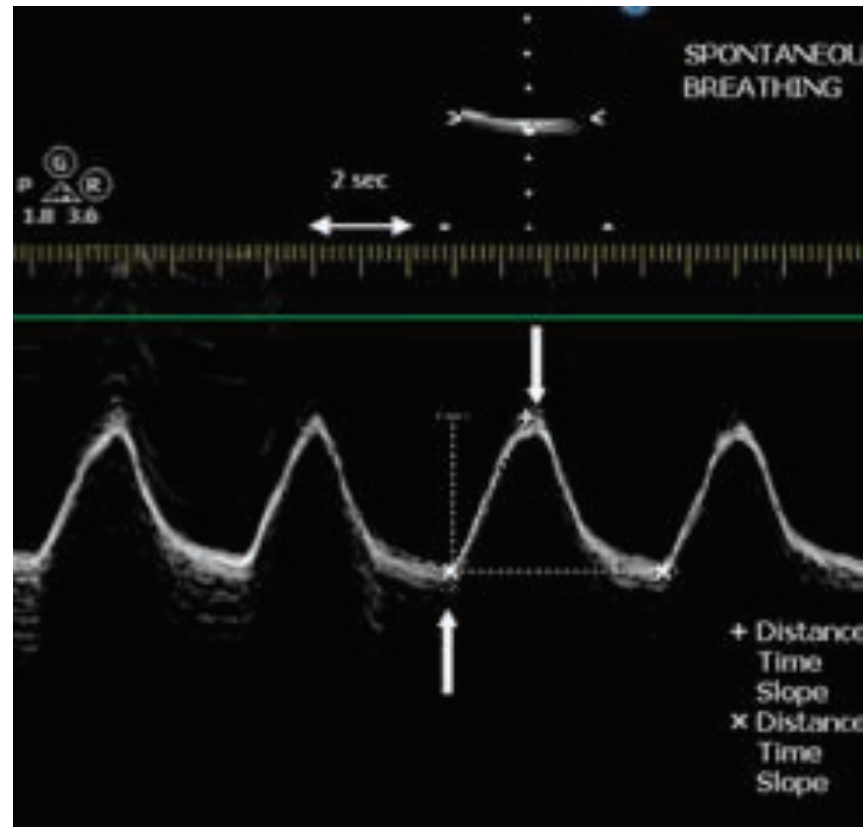
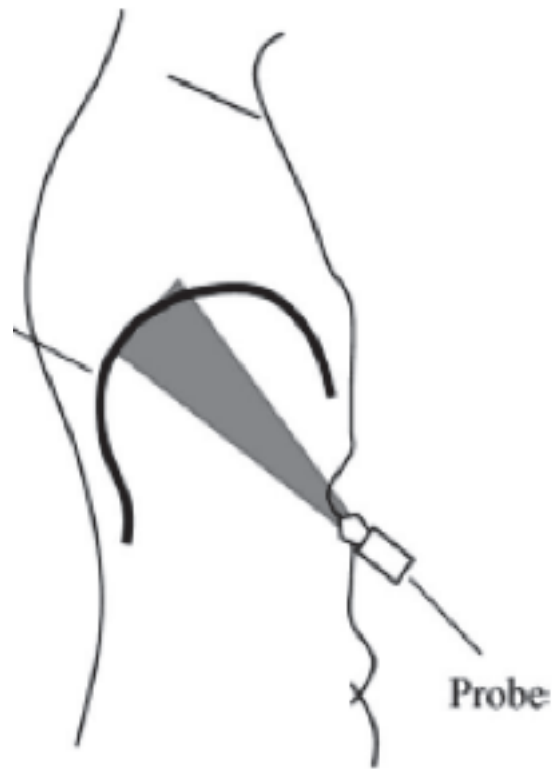




2 D

TM





Mouvement inspiratoire
est caudal

Mouvement expiratoire
est céphalique

Valeurs normales chez le sujet sain

Table 2—Right Diaphragmatic Excursions and Limit Values in Men and Women*

Variables	Men, cm	Women, cm	p Value
Quiet breathing	1.8 ± 0.3 (1.1–2.5)	1.6 ± 0.3 (1–2.2)	< 0.001
Voluntary sniffing	2.9 ± 0.6 (1.8–4.4)	2.6 ± 0.5 (1.6–3.6)	< 0.001
Deep breathing	7 ± 1.1 (4.7–9.2)	5.7 ± 1 (3.6–7.7)	< 0.001

*Data are presented as mean ± SD (5th to 95th percentile).

Faisabilité ++++

-droite: 195/210

-gauche 45/210



CHEST

Original Research

ULTRASONOGRAPHY

**Diaphragmatic Motion Studied by
M-Mode Ultrasonography***

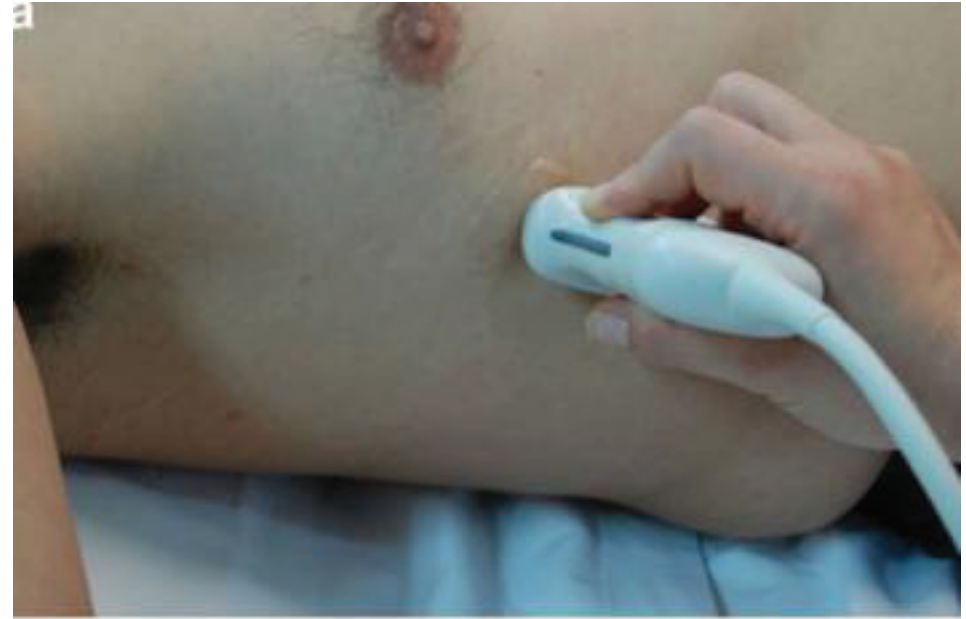
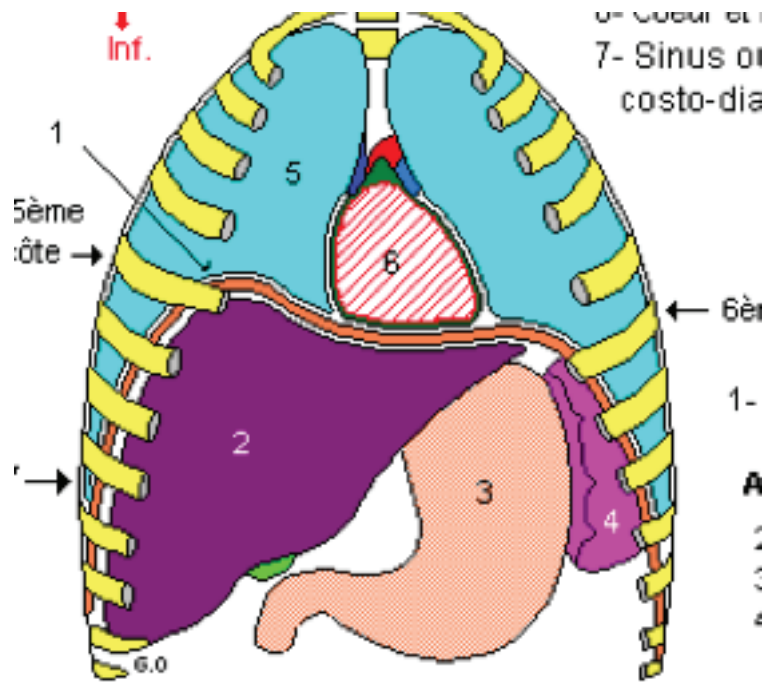
Methods, Reproducibility, and Normal Values

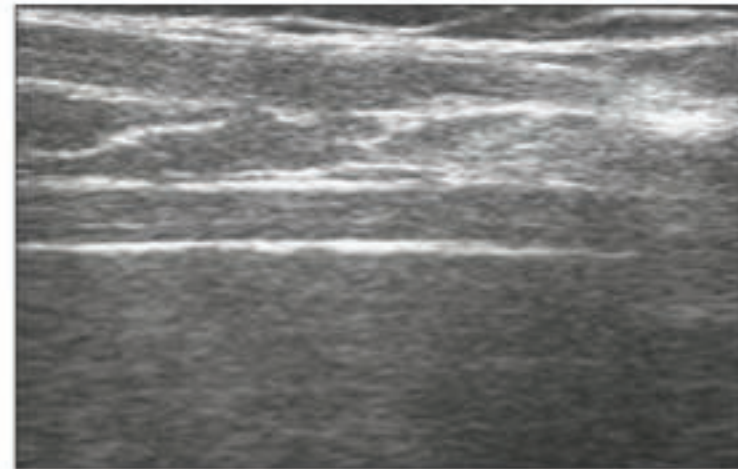
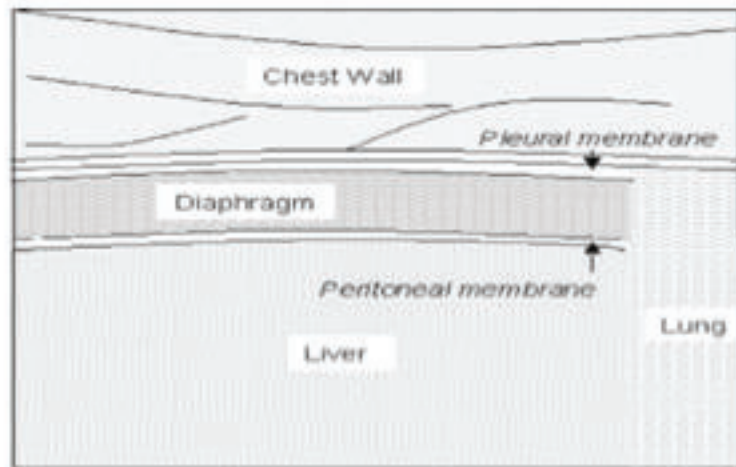
Alain Boussuges, MD, PhD; Yoann Gole, MSc; and Philippe Blanc, MD

Tableau 2 : Excursions diaphragmatiques en ventilation spontanée

	Ventilation calme	Ventilation ample
Excursion Diaphragmatique (cm)	1,99 (IQR 1,43-2,44)	5,48 (IQR 4,63-5,98)

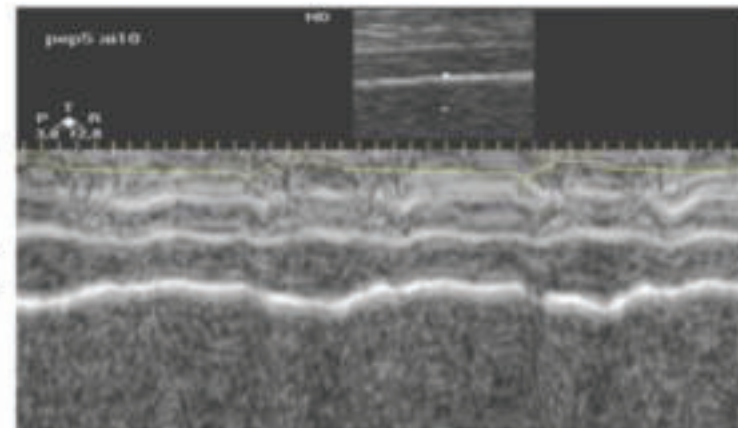
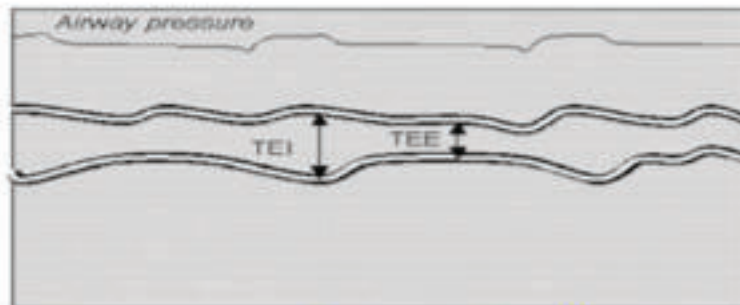
**EPAISSEUR
DIAPHRAGMATIQUE**





C

$$TF = (TEI - TEE) / TEE$$



TEI, thickness at end inspiration; TEE, thickness at end expiration.

APPLICATIONS CLINIQUES

Diaphragm dysfunction assessed by ultrasonography: Influence on weaning from mechanical ventilation*

Variables	DD Group (n = 24)	Non-DD Group (n = 58)	<i>p</i>
Demographic factors			
Age, yrs	70.1 ± 11.1	64.5 ± 12.4	.06
Male	16 (67)	34 (59)	.50
Body mass index, kg/m ²	21.1 ± 4.6	22.9 ± 4.8	.11
Comorbidity:			
Diabetes	10 (42)	33 (57)	.23
Hypertension	11 (46)	35 (60)	.33
Chronic obstructive pulmonary disease	9 (38)	19 (33)	.80
Hypothyroidism	2 (8)	1 (2)	.20
Coronary artery bypass grafting	2 (8)	1 (2)	.20
Acute respiratory distress syndrome	4 (16)	12 (21)	.77
Laboratory findings			
PaCO ₂	42.6 ± 8.3	37.3 ± 8.0	.01
PaO ₂	93.9 ± 24.1	101.3 ± 24.0	.20
FiO ₂	35.8 ± 6.5	35.9 ± 5.8	.93
Creatinine	1.1 ± 0.9	1.2 ± 1.0	.42
Sodium	139.0 ± 6.7	138.4 ± 5.4	.63
Potassium	3.7 ± 0.3	3.8 ± 0.6	.70
Calcium	8.1 ± 0.9	8.2 ± 0.9	.49
Magnesium	2.1 ± 0.2	2.1 ± 0.4	.51
Ultrasonographic findings			
DE, right, mm (IQR)	7.0 (1.8–13.5)	17.9 (14.5–22.7)	<.01
DE, right, mm (n = 11) ^a	3.0 (0.0–7.0)	18.8 (12.2–22.4)	
DE, left, mm (IQR)	7.9 (2.1–18.9)	18.0 (15.6–23.2)	<.01
DE, left, mm (n = 9) ^a	2.6 (0.0–6.2)	18.3 (12.4–23.1)	
Pleural effusion	14 (58.3)	27 (46.6)	.47
Rapid shallow breathing index	73.5 ± 23.5	55.6 ± 26.9	.01
Hospital length of stay, days (IQR)	66.0 (52.0–99.0)	42.0 (30.0–72.0)	<.01
Intensive care unit length of stay, days (IQR)	31.0 (18.5–58.5)	14.0 (10.0–33.0)	<.01

Table 2. Weaning variables of the study patients with and without DD

Variables	DD Group	Non-DD Group	<i>p</i>
Total ventilation time, hrs (IQR)	576 (374–850)	203 (109–408)	<.01
Weaning time, hrs (IQR)	401 (226–612)	90 (24–309)	<.01
Time to the spontaneous breathing trial, day (IQR)	4 (2.5–7.5)	4 (3.0–6.0)	.55
Primary weaning failure, no. (%)	20/24 (83)	34/58 (59)	<.01
Secondary weaning failure, no. (%)	10/20 (50)	10/46 (22)	.01
Died before weaning, no. (%)	4/24 (17)	12/58 (21)	.79

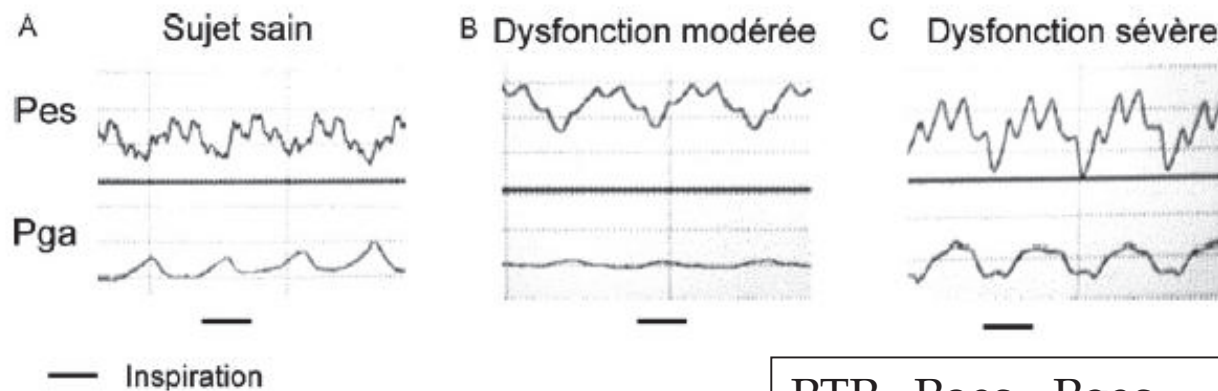
$$(T_{EI} - T_{EE})/T_{EE}$$

Emmanuel Vivier
 Armand Mekontso Dessap
 Saoussen Dimassi
 Frederic Vargas
 Aissam Lyazidi
 Arnaud W. Thille
 Laurent Brochard

Diaphragm ultrasonography to estimate the work of breathing during non-invasive ventilation

Table 2 Respiratory and ultrasonographic data

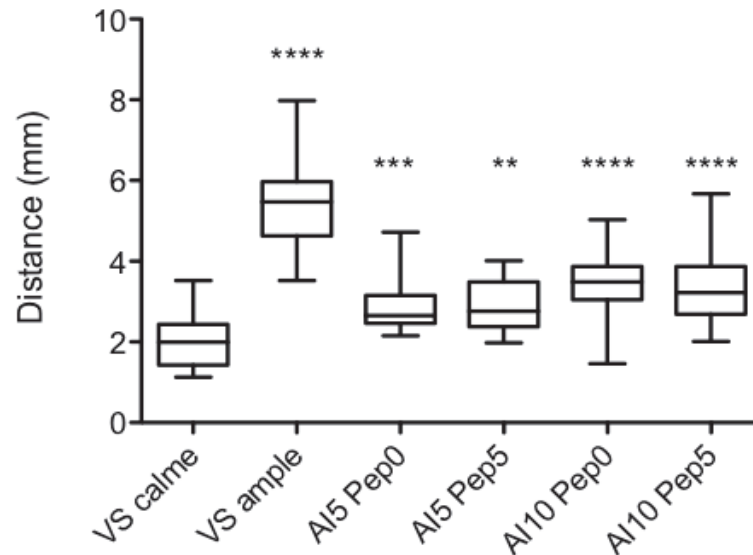
	SB	PS 5	PS 10	PS 15
V_T , mL	–	324 (231–379)	402 (374–461) [#]	445 (388–547) [#]
RR, bpm	21 (18–28)	20 (18–28)	22 (19–30)	21 (17–29)
T_{EE} , mm	2.19 (1.94–2.76)	2.26 (1.78–2.46)	2.29 (1.84–2.52)	2.27 (2.06–2.88)
T_{EI} , mm	3.08 (2.77–4.77)	3.08 (2.34–3.51)	2.73 (2.39–3.25)	2.58 (2.34–3.56)
TF, %	47.5 (35.9–63.2)	36.2 (18.6–47.2)*	22.0 (9.6–28.2)*, [#]	16.3 (9.2–20.8)*, [#]
PTP_{di} , cmH ₂ O s	13.5 (8.1–16.9)	6.2 (4.7–8.0)*	4.0 (3.3–5.4)*, [#]	2.7 (2.1–4.3)*, [#] [†]



PTP= Poes - Pgas

Tableau 3 : Excursions diaphragmatiques en Ventilation non invasive :

Niveau de pression positive	AI 5 PEEP 0	AI 5 PEEP 5	AI 10 PEEP 0	AI 10 PEEP 5
Excursion diaphragmatique droite (cm)	2,65 (IQR 2,47- 3,15)	2,77 (IQR 2,39- 3,15)	3,49 (IQR 3,05- 3,89)	3,23 (IQR 2,69- 3,87)



Hourcastagnou, Riu, Silva
Mémoire DESAR 2015

Paralysie diaphragmatique

- Mouvement paradoxale (dyskinésie diaphragmatique)

